



# A Combination of Dilatation and Stenting for Treatment of Anal Stricture: A Case Report

Ömer Faruk İnanç<sup>1</sup>, Wafi Attaallah<sup>2</sup>

<sup>1</sup>Anadolu Healthcare Center, Department of General Surgery, Kocaeli, Turkey

<sup>2</sup>Marmara University School of Medicine, Department of General Surgery, İstanbul, Turkey

## ABSTRACT

Intersphincteric resection (ISR) was introduced recently as an alternative procedure for abdominoperineal resection and sparing the anal sphincter. Anastomosis stricture is a common complication after ISR. In this study, we attempted to maintain the dilatation longer using a stent in combination with dilatation during a single session on a patient who was suffering from anal stricture after an ISR procedure. Six weeks following neoadjuvant chemo-radiotherapy, a 52-year-old woman underwent ISR. She presented to the hospital with a rectal adenocarcinoma at a 3 cm distance from the anal verge. A complete diverting tube ileostomy was performed as a protective stoma instead of a conventional loop ileostomy. The patient reported hard defecation at 6 weeks after surgery. A severe anastomosis stricture was detected during the digital rectal exam. Dilatation was performed under general anesthesia. The lumen was dilated up to 1.5 cm with Hegar dilators, and colonic mucosa were confirmed by a rigid rectoscope. A polyvinyl chloride soft tube with a length of 20 cm and a diameter of 17 mm was used as a stent to maintain the dilatation. Instead of dilatation alone, we combined dilatation with a convenient anal stent. The patient was discharged on the postoperative third day. During the 2 weeks of follow up with the tube, the patient did not report any challenges in terms of mobilization and lifestyle. There was no bleeding. However, tenesmus was described during this 2-week period by the patient. After the removal of the tube on the fourteenth day, the stricture was resolved and defecation was within normal. After a follow-up period of 2 months, there were no reported problems regarding defecation. This treatment modality could be recommended as a first-line treatment instead of surgical revision procedures (e.g., flap or stricturoplasty) in the future because it is a minimally invasive procedure.

**Keywords:** Dilatation, intersphincteric resection, rectal cancer, stricture

## Introduction

Surgery is still considered the main treatment for lower rectal cancer. Abdominoperineal resection is a common surgical procedure for these patients.<sup>1</sup> Intersphincteric resection (ISR) is a recently introduced alternative procedure for sparing the anal sphincter.<sup>2</sup> However, functional problems and postoperative complications have been reported with this approach; anastomosis stricture is a common complication after ISR.<sup>3</sup> Although Hegar dilatation of the stricture is the most common procedure used, recurrence rates are still high.<sup>4</sup> Therefore, we thought about an additional approach to maintain the dilatation longer.

In this study, a case of anal stricture after ISR, which was treated with a combination of dilatation and stenting, is introduced and discussed.

## Case Report

A 52-year-old woman with a body mass index of 29.10 kg/m<sup>2</sup> presented to the hospital with positive fecal occult blood testing and no other complaints. A colonoscopy showed a tumor at a 3 cm distance from the anal verge. Histopathological evaluations revealed a diagnosis of rectal adenocarcinoma. Preoperative staging showed no distant metastasis. Pelvic magnetic resonance imaging showed a T3 tumor without perirectal lymph node involvement. The patient had a reported history of hypertension.

Six weeks after neoadjuvant chemo-radiotherapy, she underwent ISR. After ISR was completed, a handsewn coloanal anastomosis with separated silk sutures was performed using a Lone Star retractor. A complete diverting tube ileostomy was performed as a protective stoma instead of a conventional loop ileostomy. Oral feeding was started on the first postoperative



Address for Correspondence: Wafi Attaallah, MD,  
Marmara University School of Medicine, Department of General Surgery, İstanbul, Turkey  
E-mail: drwafi2003@yahoo.com ORCID ID: orcid.org/0000-0002-3179-4144  
Received: 14.10.2022 Accepted: 08.03.2023



Copyright© 2024 The Author. Published by Galenos Publishing House on behalf of Turkish Society of Colon and Rectal Surgery. This is an open access article under the Creative Commons AttributionNonCommercial 4.0 International (CC BY-NC 4.0) License.

day. The tube ileostomy was removed at 2 weeks postop. Normal defecation occurred after the tube removal. The patient was discharged on the tenth day after surgery. Definitive pathological results showed distal rectal adenocancer (stage T2N1b).

The patient reported hard defecation 6 weeks following the surgery. A severe anastomosis stricture was detected during a digital rectal exam. The patient signed the informed consent form for the planned surgery. Dilatation was performed under general anesthesia, using Hegar dilators. After appropriate dilatation, a rigid rectosigmoidoscope was inserted through the anus. Interestingly, there was no bowel mucosa and there was a huge pouch without luminal connection. We inserted a thin dilator (diameter: 3 mm) in different directions through the anus to find the colonic orifice; it was found at the lateral wall of the pouch (Figure 1).

The lumen was dilated up to 1.5 cm with Hegar dilators, and colonic mucosa was confirmed by the rigid rectoscope. A polyvinyl chloride (PVC) soft tube with a length of 20 cm and a diameter of 17 mm was used as a stent for maintaining the dilatation. The tube (stent) was configured as shown in Figure 2. To prevent migration of the stent, the distal part of the stent was prepared as shown in Figure 3, allowing for fixture to the skin without disturbing the patient's movement and position (i.e., sitting). The stent was fixed to the skin using #0 silk sutures.

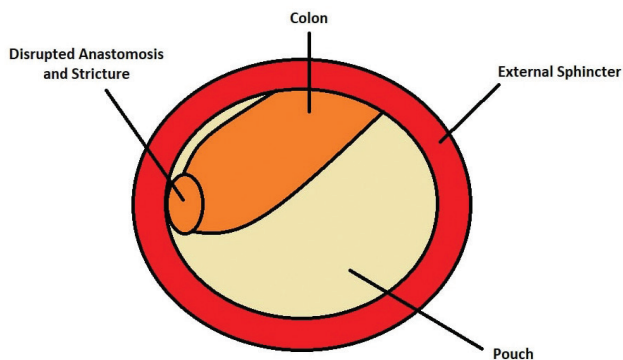


Figure 1. Schematization of Stricture



Figure 2. The Stent

Oral feeding began on postoperative day 1, and defecation through the tube occurred on postoperative day 2. The patient was discharged on the third day following surgery. During the 2 weeks of follow up, the patient did not report any challenges in terms of mobilization and lifestyle. There was no bleeding. However, tenesmus was described before removing the stent. After removal of the tube, the stricture was resolved, and the patient's defecation was normal. Since the patient rejected a colostomy, the only option was stricturoplasty. However, this was not suitable because it could interrupt the planned chemotherapy. Therefore, we thought of another minimally invasive solution, and the patient was very satisfied with the outcome of the procedure. The pouch was significantly smaller than before. After a follow-up period of 10 months, no problems regarding defecation were reported, and the pouch disappeared.

## Discussion

The most common complications of ISR are the following: anastomotic leakage, stricture, fistula, pelvic sepsis, wound complications, bleeding, bowel obstruction, and mucosal prolapse. According to the literature, the stricture rate after ISR can be up to 16%.<sup>5</sup> It is also known that ISR is an independent risk factor for the development of stricture.<sup>6</sup>

The current treatments of stricture after ISR are dilatation via Hegar dilators, endoscopic balloons, and surgical procedures including flaps, stricturoplasty, or permanent ostomy.<sup>7</sup> Hegar dilatation may cause complications such as bowel perforation, anastomotic rupture, and perirectal abscess after dilatation procedures, and further surgical intervention may be required<sup>4</sup> because the recurrence rate after dilatation is high within short periods. Therefore, in this study, we attempted to maintain the dilatation longer using a stent in combination with dilatation during a single surgery. The patient was receiving adjuvant chemotherapy, which made us hesitate to perform flap surgery. In addition, the patient refused a colostomy. As such, our options were limited.

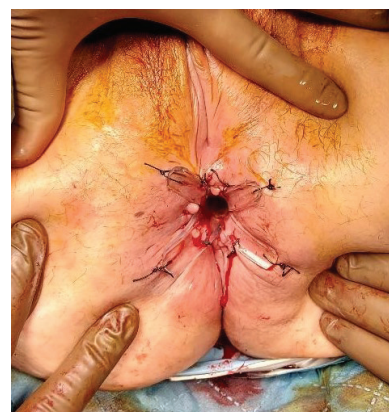

Figure 3. The Placement of the Stent

To the best of our knowledge, this is the first time this type of anal stricture management has been reported; instead of dilatation alone, we combined dilatation with a convenient anal stent. This treatment modality can be recommended as a first-line treatment instead of surgical revision procedures (e.g., flap or stricturoplasty) in the future since it is minimally invasive.

Stenting was not described for anal stricture in previous studies because it is uncomfortable and there is a high risk of migration. However, in this case, we used a flexible and convenient PVC stent which would be a good solution for both migration and discomfort. The promising results of this minimally invasive approach may lead to it becoming a first-line treatment for anal stricture in the future.

Further prospective randomized studies with a large number of patients and longer follow-up times are needed to evaluate the efficacy of this approach for anal stricture treatment.

## Conclusion

Using a convenient anal stent in combination with dilatation gave a good result for the treatment of anal stricture. This minimally invasive procedure may become a first-line treatment for anal stricture in the future.

## Ethics

**Informed Consent:** The patient signed the informed consent form for the planned surgery.

## Authorship Contributions

Surgical and Medical Practices: Ö.F.İ., W.A., Concept: Ö.F.İ., W.A., Design: Ö.F.İ., W.A., Data Collection or Processing:

Ö.F.İ., W.A., Analysis or Interpretation: Ö.F.İ., W.A., Literature Search: Ö.F.İ., W.A., Writing: Ö.F.İ., W.A.

**Conflict of Interest:** No conflict of interest was declared by the authors.

**Financial Disclosure:** The authors declared that this study received no financial support.

## References

1. Garcia-Henriquez N, Galante DJ, Monson JRT. Selection and Outcomes in Abdominoperineal Resection. *Front Oncol* 2020;10:1339.
2. Denost Q, Rullier E. Intersphincteric Resection Pushing the Envelope for Sphincter Preservation. *Clin Colon Rectal Surg* 2017;30:368-376.
3. Xv Y, Fan J, Ding Y, Hu Y, Hu Y, Jiang Z, Tao Q. Latest Advances in Intersphincteric Resection for Low Rectal Cancer. *Gastroenterol Res Pract* 2020;2020:8928109.
4. Lee SY, Kim CH, Kim YJ, Kim HR. Anastomotic stricture after ultralow anterior resection or intersphincteric resection for very low-lying rectal cancer. *Surg Endosc* 2018;32:660-666.
5. Cipe G, Muslumanoglu M, Yardimci E, Memmi N, Aysan E. Intersphincteric resection and coloanal anastomosis in treatment of distal rectal cancer. *Int J Surg Oncol* 2012;2012:581258.
6. Picazo-Ferrera K, Jaurrieta-Rico C, Manzano-Robleda M, Alonso-Lárraga J, de la Mora-Levy J, Hernández-Guerrero A, Ramírez-Solis M. Risk factors and endoscopic treatment for anastomotic stricture after resection in patients with colorectal cancer. *Rev Gastroenterol Mex* 2021;86:44-50.
7. Zhang B, Zhuo GZ, Zhao K, Zhao Y, Gao DW, Zhu J, Ding JH. Cumulative Incidence and Risk Factors of Permanent Stoma After Intersphincteric Resection for Ultralow Rectal Cancer. *Dis Colon Rectum* 2022;65:66-75.