



Colonic Metastasis of Palatine Tonsillar Melanoma Presenting as Colocolic Intussusception

Kolokolik İntususepsiyon ile Prezente Olan Palatin Tonsiller Melanomun Kolon Metastazı

© Nalinikanta Ghosh, © Ashok Kumar, © Vishwanath Reddy, © Vikrant Verma

Sanjay Gandhi Postgraduate Institute of Medical Science, Department of Surgical Gastroenterology, Lucknow, India

ABSTRACT

Primary mucosal melanomas account for 0.8%-3.7% of all the melanomas. More than half of the primary melanomas arise in the head and neck region, with nose and paranasal sinus being the most common site. Primary tonsillar mucosal melanoma is extremely rare, with only 27 cases reported in the literature till now. Incidence of metastatic melanoma to the colon, rectum and anus is 0.3%. Here, we present first case of the palatine tonsillar melanoma with isolated colonic metastasis.

Keywords: Primary tonsillar melanoma, mucosal melanoma, colonic melanoma, colocolic intussusception

ÖZ

Primer mukozal melanomlar tüm melanomların %0,8-3,7'sini oluşturur. Primer mukozal melanomların yarısından fazlası baş ve boyun bölgesinde, en sık olarak de burun ve paranasal sinüste ortaya çıkar. Primer tonsiller mukozal melanom son derece nadirdir ve şimdiye kadar literatürde sadece 27 hasta bildirilmiştir. Melanomun kolon, rektum ve anüse metastaz yapma insidansı %0,3'tür. Bildiğimiz kadarıyla bu olgu bildiriyle, izole kolon metastazı olan ilk palatin tonsiller melanom olgusunu sunuyoruz.

Anahtar Kelimeler: Primer tonsiller melanom, mukozal melanom, kolonik melanom, kolo-kolik intusepsiyon

Introduction

Primary mucosal melanomas account for 0.8%-3.7% of all the melanomas.¹ More than half of the primary melanomas arise in the head and neck region, with nose and paranasal sinus being the most common site. Primary tonsillar mucosal melanoma is extremely rare, and only 27 cases have been reported in the literature so far.² Melanomas of the gastrointestinal (GI) tract are rare, accounting for 1%-3% of the total malignant tumours of the GI tract.³ Incidence of metastatic melanoma to the colon, rectum and anus is 0.3%.⁴ Here, we present a case of palatine tonsillar melanoma with isolated colonic metastasis. This is the first case of the palatine tonsillar melanoma reported in the literature.

Case Report

A 42-year-old woman had symptoms of soreness and non-healing ulcer over left tonsillar fossa for 8 months. However, she did not undergo any evaluation or treatment for the same (Figure 1). It was progressively enlarged. There was no bleeding or hoarseness of voice. The patient was referred to us for an intermittent colicky lower abdominal pain after 4 months. Abdominal pain was associated with abdominal distension and occasional non-bilious vomiting. It relieved with the passage of flatus and stool. There was no history of rectal bleeding or acute intestinal obstruction. There was a loss of appetite and loss of weight. No history of jaundice, bony pain or respiratory distress. On examination, an ill-defined lump was found palpable over the left hypochondrium. No



Address for Correspondence/Yazışma Adresi: Ashok Kumar MS,
Sanjay Gandhi Postgraduate Institute of Medical Science, Department of Surgical Gastroenterology, Lucknow, India
E-mail: drashok97@gmail.com ORCID ID: orcid.org/0000-0003-3574-8919
Received/Geliş Tarihi: 18.04.2020 Accepted/Kabul Tarihi: 14.05.2020

hepatomegaly or splenomegaly or ascites was observed. A deeply pigmented ulcerated lesion in the left tonsillar fossa was found on oral cavity examination.

The woman was evaluated with a colonoscopy, which showed a large pedunculated ascending colon growth. Non-negotiability of colonoscope omits the possibility of endoscopic removal of tumour. The biopsy suggested malignant melanoma. A biopsy from oral ulcer also showed malignant melanoma. Contrast-enhanced CT scan (CECT) showed mildly enhancing polypoidal soft tissue lesion (4.2x4.1 cm) in the hepatic flexure with colocolonic intussusception involving hepatic flexure and ascending colon (Figure 2). Positron emission tomography (PET) scan showed FDG avid standardised uptake value (SUV: 13.7) ill-defined enhancing soft tissue density lesion arising

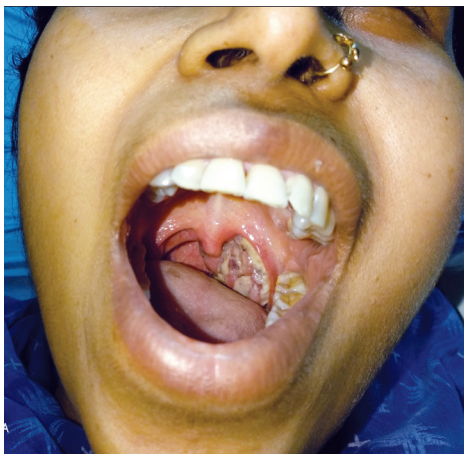

Figure 1. Oral cavity image, showing ulceroproliferative growth over left tonsillar area

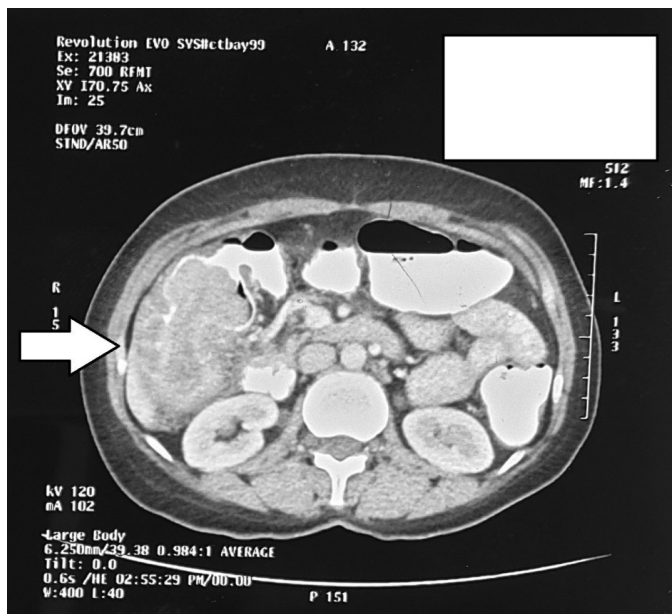


Figure 2. Contrast enhanced CT scan showing polypoidal right side colonic mass with colo-colic Intussusceptions

from the left tonsil. FDG avid (SUV: 10.8) enhancing wall thickening was noted in descending colon in the left lumbar region with evidence of colocolonic intussusceptions. The patient was taken up for surgery as the presence of colocolic intussusception was easily reducible (Figure 3). A polypoid lesion was found at the hepatic flexure of the colon. The presence of multiple hard lymph nodes were found at the middle colic artery base with a maximum size of 20 mm. She underwent extended right hemicolectomy with ileocolonic anastomosis. The postoperative course was uneventful. The woman was discharged on postoperative day 10. Gross examination showed a polypoidal pigmented growth of 6.5x7.5 cm at the hepatic flexure of the colon (Figure 4). The surface of the polyp was irregular, and the cut surface was greyish white in colour with focal blackish areas. The rest of the colon and the terminal ileum were normal. The tumour

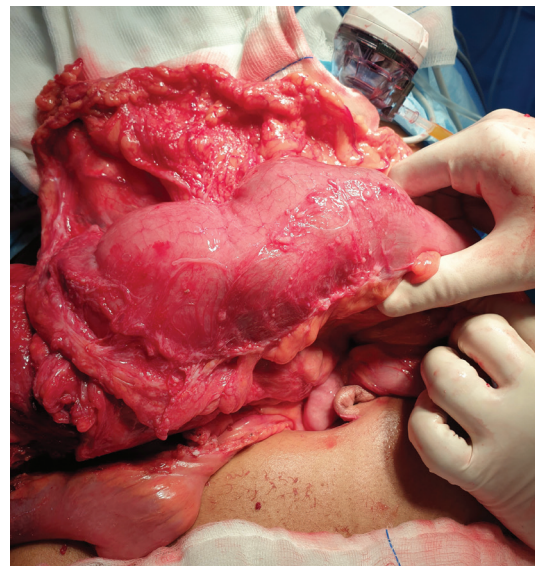


Figure 3. Intra operative picture showing manual reduction of colocolic intussusceptions

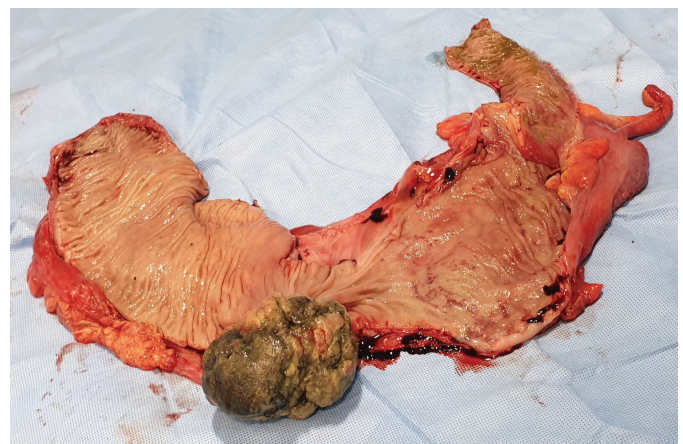

Figure 4. Extended right hemicolectomy specimen (cranial end on right side, caudal end on left side showing appendix) showing a polypoidal lesion.

was composed of neoplastic cells disposed in fascicles and sheets. Tumour cells showed anisonucleosis, spindle nuclei and vesicular chromatin with focal pigmentation. Twenty-one lymph nodes were retrieved in total, and 12 among them were positive for metastasis. On immunohistochemistry, the tumour cells were immunoreactive for vimentin, S100 and HMB45 and non-reactive for SMA, desmin, CD117 and DOG1 (Figure 5). At 1-month follow-up, she was found to be resumed her normal routine work. She was regular in her follow-up for tonsillar lesion and had planned for four cycles of methotrexate and 20 Gy in 5 fractions palliative radiotherapy.

Discussion

Melanoma of palatine tonsil and that of GI tract is rare. The small bowel is found to be most commonly affected in the GI tract melanoma.⁵ GI metastases usually appear as multiple polypoid lesions. It can be melanotic or amelanotic. Our case was a solitary lesion with melanotic appearance. Clinical presentation in the large bowel pathology is mostly obstruction, bleeding or perforation. Metastatic melanoma presenting as intussusception is usually seen in the small bowel, but in our patient, large bowel lesion was presented with colocolic intussusceptions. Patients with GI tract involvement are found to have more than 50% metastatic melanoma involving other sites and organs.⁶ In our case, there were no other sites of metastasis. Histopathological examination and immunohistochemistry are used for diagnosis. Prognosis is poor with median survival rate of less than 1 year. The 5-year survival rate is less than 10%. However, development in molecular biology has added a different dimension to management of these tumours.

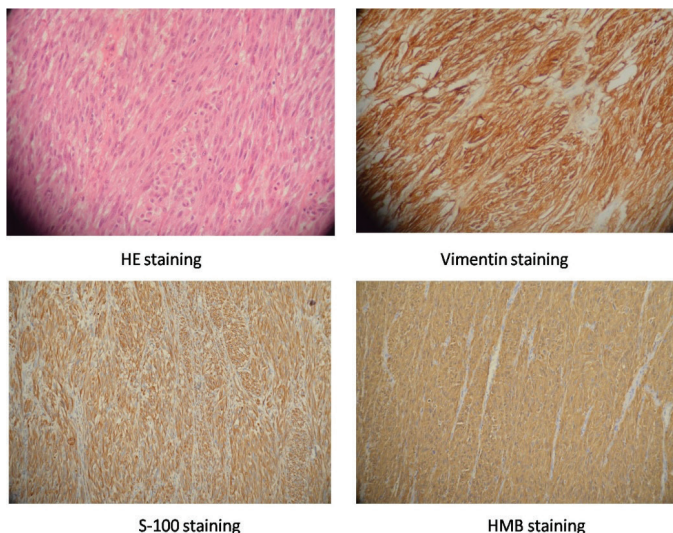


Figure 5. Histopathological examination showing classical pattern in hematoxylin and eosin staining and marker of melanoma viz. vimentin, S-100 and HMB-45 staining

BRAF mutation (V600E) is a molecular target for treatment. Studies have shown the effect of BRAF inhibitors, such as dabrafenib, significantly improved progression-free survival in melanoma.^{7,8} Complete surgical resection may provide long-term, disease-free survival as reported by Ollila et al.⁹

Acknowledgment: I wish to thank Prof V.K Kapoor, Department of Surgical Gastroenterology, Sanjay Gandhi Postgraduate Institute of Medical Science, Lucknow, India, for his guidance and moral support.

Ethics

Informed Consent: Written informed consent was obtained from the patient for publication and any accompanying images.

Peer-review: Externally peer reviewed.

Authorship Contributions

Surgical and Medical Practices: N.G., A.K., V.R., V.V., Concept: A.K., Design: A.K., Data Collection or Processing: V.V., Analysis or Interpretation: N.G., Literature Search: N.G., V.R., Writing: N.G.

Conflict of Interest: No conflict of interest was declared by the authors.

Financial Disclosure: The authors declared that this study received no financial support.

References

- López F, Rodrigo JP, Cardesa A, Triantafyllou A, Devaney KO, Mendenhall WM, Haigentz M Jr, Strojan P, Pellitteri PK, Bradford CR, Saha AR, Hunt JL, de Bree R, Takes RP, Rinaldo A, Ferlito A. Update on primary head and neck mucosal melanoma. *Head Neck* 2016;38:147-155.
- Osorio M, Moubayed SP, Hernandez-Prera J, Scott JC, Urken ML. Primary mucosal melanoma of the palatine tonsil: Report of a case and review of the literature. *Am J Otolaryngol* 2017;38:501-504.
- Blecker D, Abraham S, Furth EE, Kochman ML. Melanoma in the gastrointestinal tract. *Am J Gastroenterol* 1999;94:3427-3433.
- Park JS, Ng KS, Saw RPM, Thompson JF, Young CJ. Metastatic Melanoma to the Colon, Rectum, and Anus: A 50-Year Experience. *Ann Surg Oncol* 2018;25:2178-2183.
- Elsayed AM, Albahra M, Nzeako UC, Sobin LH. Malignant melanomas in the small intestine: a study of 103 patients. *Am J Gastroenterol* 1996;91:1001-1006.
- Caputy GG, Donohue JH, Goellner JR, Weaver AL. Metastatic melanoma of the gastrointestinal tract. Results of surgical management. *Arch Surg* 1991;126:1353-1358.
- Hauschild A, Grob JJ, Demidov LV, Jouary T, Gutzmer R, Millward M, Rutkowski P, Blank CU, Miller WH Jr, Kaempgen E, Martín-Algarra S, Karaszewska B, Mauch C, Chiarion-Sileni V, Martin AM, Swann S, Haney P, Mirakhur B, Guckert ME, Goodman V, Chapman PB. Dabrafenib in BRAF-mutated metastatic melanoma: a multicentre, open-label, phase 3 randomised controlled trial. *Lancet* 2012;380:358-365.
- Flaherty KT, Puzanov I, Kim KB, Ribas A, McArthur GA, Sosman JA, O'Dwyer PJ, Lee RJ, Grippo JF, Nolop K, Chapman PB. Inhibition of mutated, activated BRAF in metastatic melanoma. *N Engl J Med* 2010;363:809-819.
- Ollila DW, Essner R, Wanek LA, Morton DL. Surgical resection for melanoma metastatic to the gastrointestinal tract. *Arch Surg* 1996;131:979-980.