

# Mechanical Small-Bowel Obstruction due to Ileal endometriosis

## “İleal Endometriyozis Nedeniyle Oluşan Mekanik İnce Bağırsak Obstrüksiyonu” Olgu Sunumu

Ünal Sabancı<sup>1</sup>, Taner Oruç<sup>1</sup>, Burcu Gül<sup>2</sup>

<sup>1</sup>Medicana Kadıköy Hospital, Clinic of General Surgery, İstanbul, Turkey

<sup>2</sup>Medicana Kadıköy Hospital, Clinic of Radiology, İstanbul, Turkey

### ABSTRACT

Mechanical small-bowel obstruction is a very common surgical emergency, but obstruction due to endometriosis is very rare, and only a few cases have been reported in the literature. Herein, we present the case of a 28-year-old female who presented with abdominal pain, loss of appetite, nausea and vomiting. Plain abdominal X-ray showed multiple air-fluid images. Abdominal computed tomography revealed dilated ileal segments and air-fluid images. The patient underwent a partial ileum resection + ileo-ileostomy. In the histopathological examination, endometriosis was confirmed between the ileal segments.

**Keywords:** Endometriosis, mechanical ileus, mechanical small bowel obstruction

### ÖZ

Mekanik ince bağırsak obstrüksiyonu çok yaygın bir cerrahi acil durumdur, fakat endometriyozise bağlı olanına çok nadir rastlanır. Literatürde birkaç olgu sunumu vardır. Buradaki olguda 28 yaşında bir kadın hasta karın ağrısı, iştahsızlık, bulantı ve kusma şikayetleri ile başvurdu. Abdominal bilgisayarlı tomografide multipl hava-sıvı seviyeleri vardı. Abdominal bilgisayarlı tomografide genişlemiş ileum segmentleri ve hava-sıvı seviyeleri vardı. Hastaya parsiyel ileum rezeksiyonu + ileo-ileostomi ameliyatı yapıldı. Histopatolojik incelemede ileal segmentler arasında endometriyozis varlığı rapor edildi.

**Anahtar Kelimeler:** Endometriyozis, mekanik ileus, mekanik ince bağırsak obstrüksiyonu

### Introduction

Mechanical intestinal obstruction is one of the most common surgical emergencies with a very wide spectrum of causes. The possible causes include external compression (adhesions, hernia), changes in the bowel wall (tumour, inflammation/infection) and blockage of the lumen (coprostanis, intussusception). The passage of intestinal contents can be blocked either partially (sub-ileus, incomplete ileus) or totally (complete ileus). Mechanical ileus more often affects the small bowel than the large bowel, in a ratio of 4:1.<sup>1</sup>

Small-bowel ileus is usually caused by adhesions from prior surgery (65%) or hernia (15%), while large-bowel ileus is

usually caused by cancer (70%) or by adhesions and stenoses after a recurrent diverticulitis (up to 10%).<sup>1</sup>

The clinical manifestations of ileus and their degree of severity depend to a large extent on the blockage site. Thus, the common manifestations of small-bowel ileus include nausea and vomiting, cramps, bloating and retention of stool and flatus. The more proximally located the pathological process is, the more rapidly the patient becomes symptomatic with the vomiting of undigested food. The diagnostic evaluation of mechanical ileus is as follows: In the physical examination, the abdomen is distended and intensified bowel sounds are a classic finding in the early



Address for Correspondence/Yazışma Adresi: Ünal Sabancı, MD,  
Medicana Kadıköy Hospital, Clinic of General Surgery, İstanbul, Turkey  
E-mail: usabanci@yahoo.com ORCID ID: orcid.org/0000-0002-0722-4969  
Received/Geliş Tarihi: 15.04.2020 Accepted/Kabul Tarihi: 28.05.2020

phase. There is no specific laboratory test for the assessment of mechanical ileus in the early phase.<sup>2</sup> In the late phase, bowel ischaemia may occur and the levels of acute phase reactants increase. Procalcitonin concentration seems to be a potentially useful marker.<sup>3</sup> Abdominal ultrasonography in the emergency room is still a useful means of detecting free fluid or an incarcerated hernia. It plays a less important role in the evaluation of ileus, as its utility is limited by artefact from air in the distended abdomen.<sup>4</sup> An abdominal plain film in the standing or lateral position is inexpensive and can be readily obtained, but it is also relatively insensitive and nonspecific.<sup>5</sup> Abdominal computed tomography (CT) is more than 90% sensitive and specific for the diagnosis of mechanical ileus and is thus the gold standard.<sup>6</sup> It enables the assessment of the degree of severity (complete versus incomplete ileus), precise localisation (caliber difference) and determination of the cause (incarcerated hernia, tumour, inflammatory changes), along with the detection of potential complications (ischaemia, perforation).

### Case Report

A 28-year-old female patient was admitted to the emergency service with complaints of abdominal pain, loss of appetite, nausea and vomiting. The abdominal pain started in the epigastric region one day ago and radiated to the whole abdomen in 6 h. The character of the pain was crampy and lasted for ~1 min, then gradually decreased. She had no remarkable past medical history. In the physical examination, abdominal tenderness in the whole abdomen and rebound tenderness were positive. The lab test showed mild leukocytosis. Abdominal USG was inconclusive because of gas. Plain abdominal X-ray showed multiple air-fluid images (Figure 1). IV contrasted tomography showed dilatation and wall thickening of the whole ileum (Figure

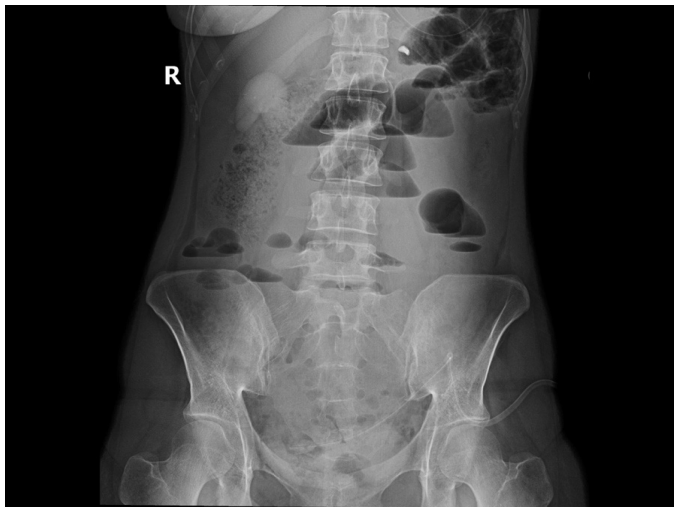

Figure 1. Plain Abdominal X-ray

2, 3). The patient's complaints, physical examination and abdominal CT findings were compatible with a diagnosis of mechanical small-bowel obstruction with an unknown etiology. The patient underwent a laparotomy, which revealed a big gato formation of the distal ileum that lead to a 15-cm complete obstruction and a proximal ileocecal valve. It was impossible to dissect the gato formation; therefore, we decided to perform a parietal ileum resection and primary anastomosis. Postoperative follow-up was uneventful, and the patient was discharged on the fourth postoperative day without any complications. Postoperative histopatological examination of the specimen was reported as fibrosis caused by endometriosis (Figure 4, 5)

### Discussion

There are many causes of mechanical small-bowel obstruction. Ninety percent of obstructions without peritonitis resolve

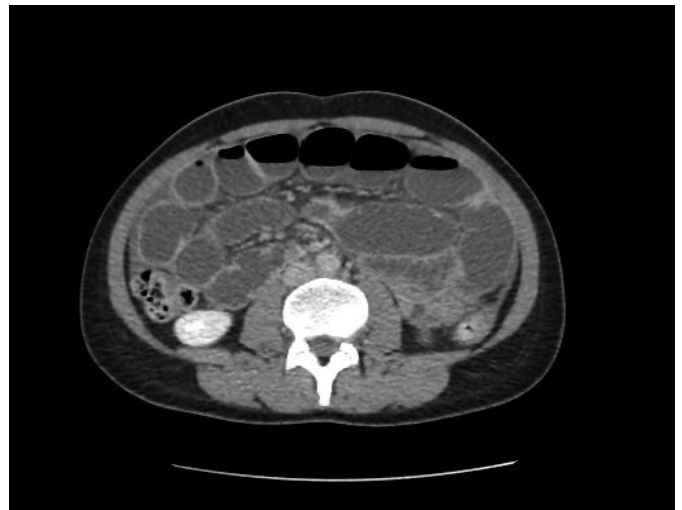

Figure 2. Abdominal CT  
CT: Computed tomography

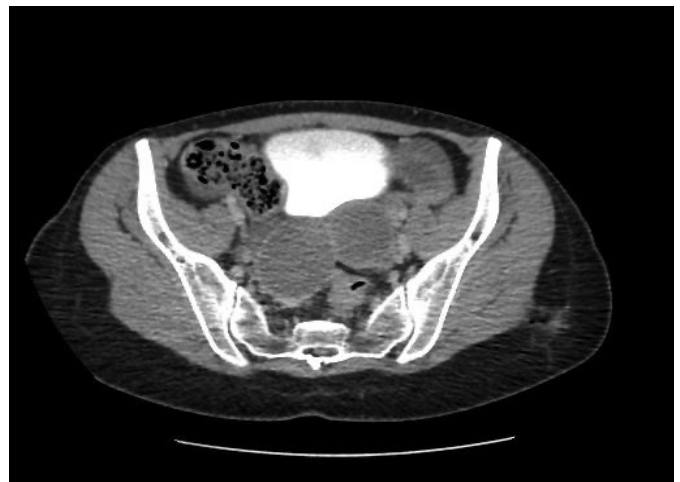

Figure 3. Abdominal CT  
CT: Computed tomography

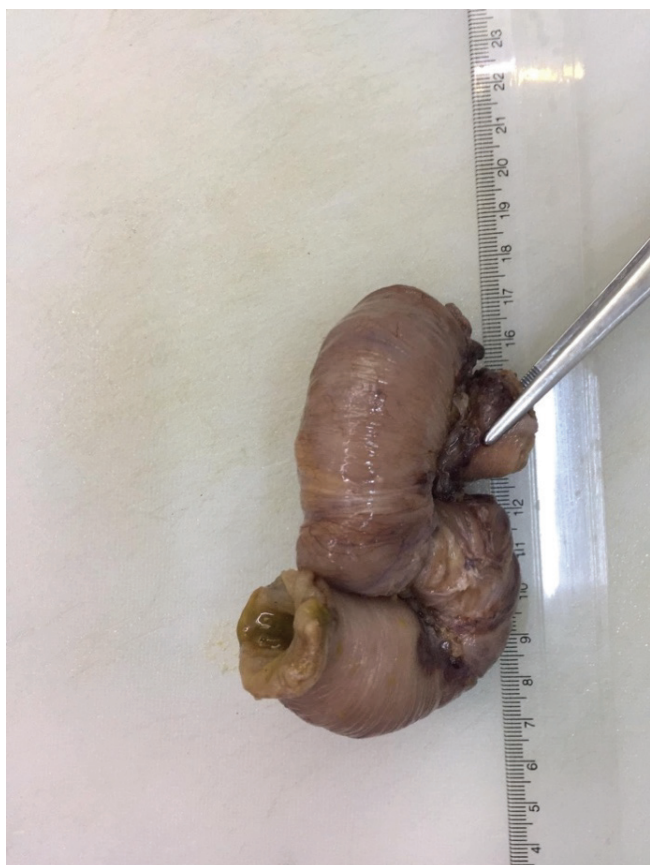

Figure 4. Macroscopic image of the Specimen

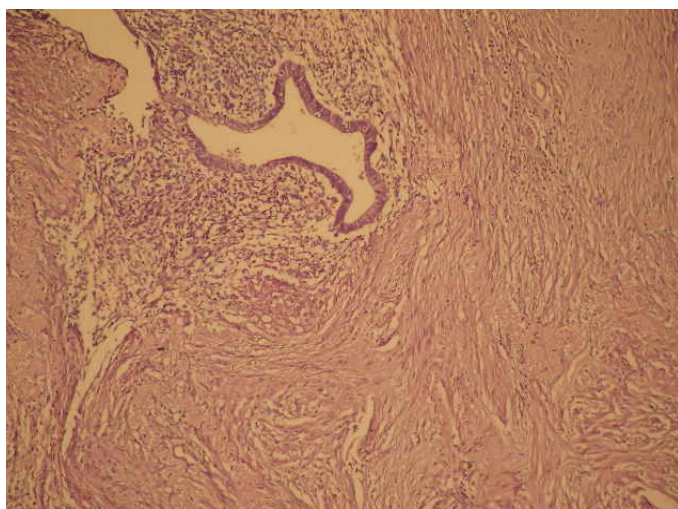


Figure 5. Microscopic image of the Specimen

spontaneously.<sup>7</sup> To avoid unnecessary laparotomies, an accurate anamnesis and physical examination, laboratory tests and radiological imaging studies should be done.

Bowel endometriosis occurs in ~10% of all cases of endometriosis<sup>8,9</sup> and usually arises in the rectum and sigmoid colon in 80% of these cases.<sup>10</sup> It is usually asymptomatic, but may cause nonspecific symptoms, such as abdominal

colic-like pains, nausea, vomiting and general symptoms of intestinal obstruction.<sup>11</sup> Obstruction due to small-bowel endometriosis does not spontaneously resolve. Since small bowel is totally intraperitoneal and adhesions are very sticky and firm, the bowel can, therefore, be easily twisted. Bowel endometriosis cannot be easily diagnosed, and it should be suspected by the clinician if the patient has a history of endometriosis. In our patient, the USG and abdominal CT showed unperforated ovarian cysts, but this was not sufficient to confirm the endometriosis. Since there were no signs of peritonitis and sepsis, we decided to manage the patient conservatively.

The patient was hospitalised and medical treatment started (NG decompression, NPO, IV fluid and electrolyte replacement, antibiotics and analgesics). After 24 h of follow-up, the clinical status of the patient did not improve, and a laparotomy was then performed. We explored all the intestine and found the gato formation of the distal ileum measuring 15 cm and a proximal ileocecal valve. Due to the complex adherence of the affected ileum, we decided to perform a partial ileal resection (~30 cm) with a primary side-to-side anastomosis. During the surgery, we suspected an intestinal endometriosis, but found the real cause of the adhesion after the pathological investigation. In the literature, ileal mechanical obstruction due to endometriosis is a rear condition. In our case, we did not suspect endometriosis preoperatively. Bilateral ovarian cysts could be remarkable; however, we could do the same algorithm.

In conclusion: Mechanical small-bowel obstruction due to ileal endometriosis is a rare case, but should be in consideration. It does not resolve spontaneously and surgery is the treatment of choice.

**Informed Consent:** Obtained.

**Peer-review:** Internally peer reviewed.

#### Authorship Contributions

Surgical and Medical Practices: Ü.S., T.O., Concept: Ü.S., Design: Ü.S., Data Collection or Processing: Ü.S., B.G., Analysis or Interpretation: Ü.S., Literature Search: Ü.S., Writing: Ü.S.

**Conflict of Interest:** No conflict of interest was declared by the authors.

**Financial Disclosure:** The authors declared that this study received no financial support.

#### References

1. Drozd W, Budzynski P. Change in mechanical bowel obstruction demographic and etiological patterns during the past century: observations from one health care institution. *Arch Surg* 2012;147:175-180.
2. Leung AM, Vu H: Factors predicting need for and delay in surgery in small bowel obstruction. *Am Surg* 2012;78:403-407.

3. Cosse C, Regimbeau JM, Fuks D, Mauvais F, Scotte M: Serum procalcitonin for predicting the failure of conservative management and the need for bowel resection in patients with small bowel obstruction. *J Am Coll Surg* 2013;216:997-1004.
4. Suri S, Gupta S, Sudhakar PJ, Venkataramu NK, Sood B, Wig JD. Comparative evaluation of plain films, ultrasound and CT in the diagnosis of intestinal obstruction. *Acta Radiol* 1999;40:422-428.
5. Thompson WM, Kilani RK, Smith BB, Thomas J, Jaffe TA, Delong DM, Paulson EK. Accuracy of abdominal radiography in acute small-bowel obstruction: does reviewer experience matter? *Am J Roentgenol* 2007;188:W233-W238.
6. Branco BC, Barmparas G, Schnuriger B, Inaba K, Chan LS, Demetriades D: Systematic review and meta-analysis of the diagnostic and therapeutic role of water-soluble contrast agent in adhesive small bowel obstruction. *Br J Surg* 2010;97:470-478.
7. Catena F, Di Saverio S, Coccolini F, Ansaloni L, De Simone B, Sartelli M, Van Goor H. Adhesive small bowel adhesions obstruction: evolutions in diagnosis, management and prevention? *World J Gastrointest Surg* 2016;8:222-231.
8. Forsgren H, Lindhagen J, Melander S, Wägermark J. Colorectal endometriosis. *Acta Chir Scand* 1983;149:431-435.
9. Jubanyik KJ, Comite F. Extrapelvic endometriosis. *Obstet Gynecol Clin North Am* 1997;24:411-440.
10. Athmanathan N, Sehdev VK, Walsh TH. Endometriosis of the sigmoid colon: a diagnostic problem. *Br J Clin Pract* 1990;44:658-660.
11. Kim JS, Hur H, Min BS, Kim H, Sohn SK, Cho CH, Kim NK. Intestinal endometriosis mimicking carcinoma of rectum and sigmoid colon: a report of five cases. *Yonsei Med J* 2009;50:732-735.
12. Pisanu A, Deplano D, Angioni S, Ambu R, Uccheddu A. Rectal perforation from endometriosis in pregnancy: case report and literature review. *World J Gastroenterol* 2010;16:648-651.