



# Iatrogenic Colon Perforation Due to Colonoscopy Presenting as a Diffuse Subcutaneous Emphysema

## Diffüz Subkutanöz Amfizem ile Prezente Olan Kolonoskopiye Bağlı İatrojenik Kolon Perforasyonu

Ömer Faruk Can, Ahmet Bozdağ

Fırat University Faculty of Medicine, Department of General Surgery, Elazığ, Turkey

### ABSTRACT

Colonoscopy is a procedure frequently used for the screening, diagnosis and treatment of colorectal diseases. While colonoscopy is generally accepted as a safe procedure, it may lead to morbidity and mortality with serious complications such a colon perforation. This risk is higher when interventional procedures are applied. After colon perforation, extracolonic gas can pass into embryologically relevant body compartments. Free air due to perforation has been reported in the thorax, mediastinum, neck, scrotum and lower extremities. Herein, we present a patient who presented with diffuse subcutaneous emphysema after a colonoscopic procedure to investigate the aetiology of anaemia.

**Keywords:** Colonoscopy, iatrogenic colon perforation, subcutaneous emphysema

### ÖZ

Kolonoskopi; kolorektal hastalıkların taraması, tanısı ve terapötik amaçla sıklıkla uygulanan bir işlemdir. Kolonoskopi genellikle güvenli bir prosedür olarak kabul edilirken, kolon perforasyonu gibi ciddi komplikasyonlarla mortalite ve morbitideye sebep olabilmektedir. Girişimsel prosedürler uygulandığında bu risk daha yüksektir. Kolon perforasyonunu takiben ekstrakolonik gaz, embriyolojik olarak ilişkili vücut bölmelerine geçebilir. Toraks, mediasten, boyun, skrotum ve alt ekstremitelerde perforasyona bağlı serbest hava bildirilmiştir. Biz anemi etiyojisi araştırmak amacı ile yapılan bir kolonoskopik işlem sonrası yaygın subkutanöz amfizemle karşılaştığımız bir hastayı sunacağız.

**Anahtar Kelimeler:** Kolonoskopi, iatrojenik kolon perforasyonu, deri altı amfizem

## Introduction

Colonoscopy has been widely accepted after its introduction in clinical use in the 1960s and has now become the main examination method in the screening, diagnosis, and treatment of colorectal diseases.<sup>1</sup> Complications that may occur after colonoscopy are colon perforation, gastrointestinal bleeding, intraabdominal organ injury and cardiopulmonary disorders. Although iatrogenic perforation is rare, it can cause serious morbidity and mortality.<sup>2</sup> With the increase of therapeutic interventions in colonoscopic examinations, perforation rates increased according to diagnostic colonoscopic examinations. In literature, ratios

ranging from 0.03% to 0.8% for diagnostic colonoscopy and 0.15% to 3% for therapeutic colonoscopy have been reported.<sup>3</sup> Risk factors for colon perforation include age; female gender; multiple comorbidities; low body mass index; low plasma albumin level; presence of underlying intestinal pathology such as Crohn's disease and previous colon surgery; patients who underwent treatment procedures such as polypectomy, dilation and endoscopic mucosal resection; patients from the intensive care unit and doctors' experience. Depending on whether the perforation area is intraperitoneal, extraperitoneal or combined, free air travels in different anatomical and facial planes, causing clinical symptoms and signs.<sup>3,4,5</sup> We present a case of combined iatrogenic



Address for Correspondence/Yazışma Adresi: Ömer Faruk Can MD,  
Fırat University Faculty of Medicine, Department of General Surgery, Elazığ, Turkey  
E-mail: o.f.cann@gmail.com ORCID ID: orcid.org/0000-0002-5577-2126  
Received/Geliş Tarihi: 11.01.2020 Accepted/Kabul Tarihi: 19.05.2020

colon perforation, which resulted in a diffuse subcutaneous emphysema after the procedure.

## Case Report

A 76-year-old female patient who presented to the general surgery outpatient clinic with a complaint of abdominal pain and had no pathological findings other than anaemia was prescribed a diagnostic colonoscopy. The patient had a history of hypertension and chronic obstructive pulmonary disease. After intestinal cleansing with preparations that have an osmotic effect, the procedure was performed on the patient. The examination was performed up to the level of the terminal ileum. Three polyps of 7-8 mm in diameter were observed in the transverse colon and the polyps were completely removed by forceps. In the sigmoid colon, a region with a suspected closed perforation was reported. Thoracic and rectal contrast-enhanced abdominal tomography was performed after the patient had a complaint of swelling and crepitation, particularly in the abdominal wall and neck, diffusing up to the eyelids in the follow-up of the patient two hours after the procedure. In her tomography, pneumoperitoneum, pneumomediastinum, pneumothorax and diffuse subcutaneous emphysema were reported. The patient's surgery was performed at the fourth hour after the procedure because of the development of an acute abdomen in the patient's serial examination. Due to being elderly and the comorbid diseases, a decision for an open surgery was made, and we entered the abdomen via a median incision under the navel. There was approximately 50 cc of reactional serous fluid in the abdomen at exploration. Common air values were seen in the mesocolon 10 cm above the pelvic peritoneum and a perforation area of approximately 1.5 cm in diameter was observed when the peritoneum was opened. Widespread air was seen in the mesocolon 10 cm above the pelvic peritoneum. No perforation was observed on the antimesenteric face. When the mesenteric peritoneum was opened, there was a 1.5 cm diameter perforation area. As the patient's Mannheim peritonitis index was low, a primary repair decision was made, and the first layer was repaired continuously with absorbable vicryl, while the second layer was repaired interruptedly with silk sutures. On the fourth postoperative day, the patient was discharged with full recovery.

## Discussion

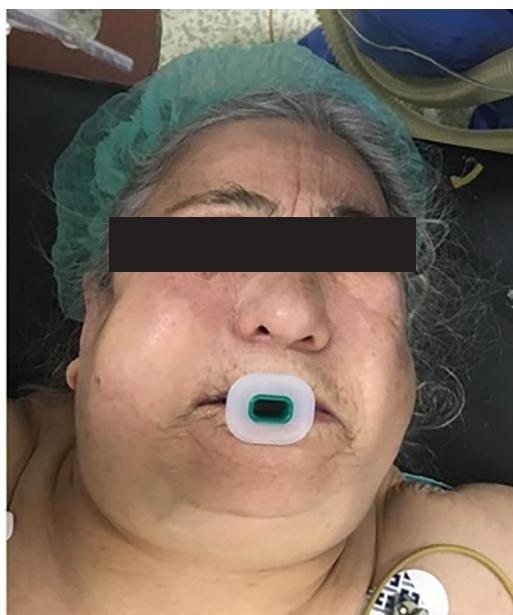Although colonoscopy has been used recently, it has taken its place in the clinic as an important method in the diagnosis, screening and treatment of colorectal diseases. Complications after colonoscopy are rare but may cause serious morbidity and mortality. Colon perforation is the most common

complication encountered during colonoscopy. Other than perforation, bleeding, intraabdominal organ injury and cardiopulmonary complications may occur. The fact that the increased number of therapeutic colonoscopies has shown that perforation during therapeutic colonoscopy is seen as more common than in diagnostic colonoscopies. In the literature, rates of 0.03%-0.8% for diagnostic colonoscopy and 0.15%-3% for therapeutic colonoscopy have been reported.<sup>3</sup> In an article published in our country, the rate in all the colonoscopic procedures was 0.05%, whereas it was reported 0.1% in therapeutic colonoscopy and 0.003% in diagnostic procedures.<sup>4</sup>

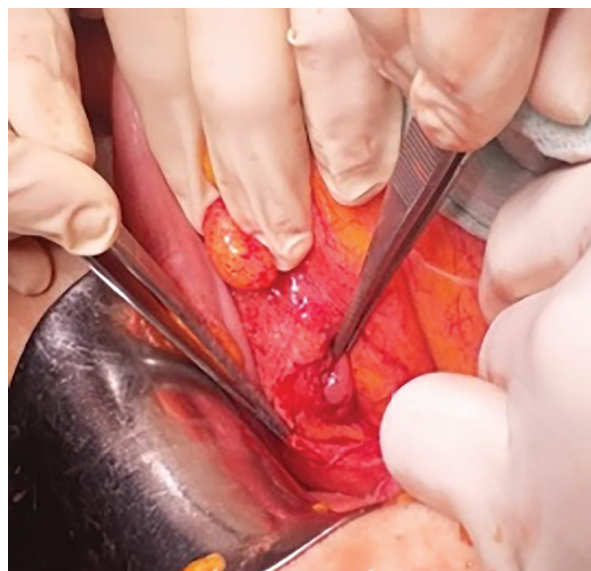It is emphasized that three factors are important in the formation of iatrogenic colon perforations; mechanical effect, mucosal damage due to therapeutic interventions and/or increase in lumen pressure due to air insufflation are effective. In literature, ratios ranging from 0.03% to 0.8% for diagnostic colonoscopy and 0.15% to 3% for therapeutic colonoscopy have been reported.<sup>3</sup> Risk factors for colon perforation include age; female gender; multiple comorbidities; low body mass index; low plasma albumin level; presence of underlying intestinal pathology such as Crohn's disease and previous colon surgery, patients who underwent treatment procedures such as polypectomy, dilation and endoscopic mucosal resection; patients from the intensive care unit and doctors' experience.<sup>3,5</sup> Our patient was elderly and had comorbid diseases.

Colon perforations can be intraperitoneal, extraperitoneal (retroperitoneal) or combined. Intraperitoneal perforations are the most common; patients present with abdominal pain and acute abdominal signs.<sup>6</sup> In extraperitoneal perforations, free air spreads to the mediastinum, thoracic cavity, pericardial space, abdominal space and subcutaneous space due to the continuity in the fascial planes described by Maunder et al.<sup>7</sup> Accordingly, clinical symptoms and signs occur. In our case, a combined type perforation was involved. There was free air in the intraabdominal area and other cavities.

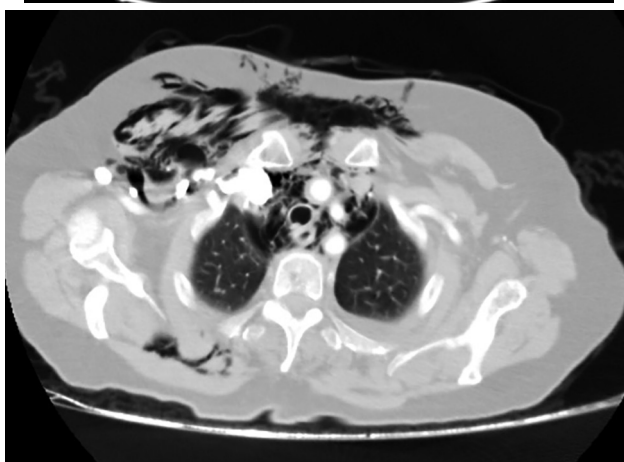
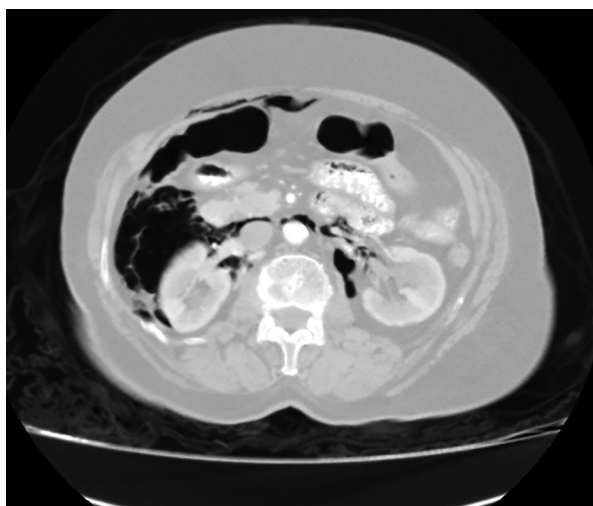
Iatrogenic colon perforation is frequently observed in the sigmoid colon as in our patient. The second most often occurs in the cecum. There are many factors affecting patients' clinical status. These can be listed as the place of perforation, adequacy of colon cleansing, period between the procedure and the hospital admission, age and presence of comorbid diseases. Patients with perforation determined during the procedure have a better clinical course. However, in patients with late determination and septic symptoms, the course is worse.<sup>8,9,10</sup> Although our patient is elderly and has comorbid diseases, there was no morbidity due to adequate bowel cleaning and early intervention (Figure 1, 2, 3, 4).



**Figure 1.** Swelling due to subcutaneous emphysema is seen around the eyes, face and neck



**Figure 4.** Perforation area in the antimesenteric area in the colon



**Figure 2, 3.** Pneumoperitoneum, pneumomediastinum, pneumothorax and diffuse subcutaneous emphysema on computed tomography

The treatment should be decided according to patients' clinical status and hospital admission period. Non-operative follow-up, endoscopic clip, primary repair, resection anastomosis and colostomy are the methods to be performed.<sup>9,11</sup> We treated the patient with primary repair since peritoneal contamination was not excessive in patients' abdominal exploration.

As a result, it is the most common complication seen after colonoscopy. Diffuse subcutaneous emphysema after perforation is a rare condition, especially in elderly patients with comorbid diseases. It is therefore necessary to be careful about the follow-up and complications.

#### **Ethics**

**Informed Consent:** Obtained.

**Peer-review:** Externally peer reviewed.

#### **Authorship Contributions**

**Concept:** Ö.F.C., A.B., **Design:** Ö.F.C., A.B., **Data Collection or Processing:** Ö.F.C., A.B., **Analysis or Interpretation:** Ö.F.C., A.B., **Literature Search:** Ö.F.C., A.B., **Writing:** Ö.F.C., A.B.

**Conflict of Interest:** No conflict of interest was declared by the authors.

**Financial Disclosure:** The authors declared that this study received no financial support.

#### **References**

1. Baş G, Okan İ, Erözgen F, Eryılmaz R, Alimoğlu O, Işık A, Özka OV, Güzey D, Kaplan R, Şahin M. Management of Iatrogenic Colonic Perforations Related to Colonoscopic Examination. *Turk J Colorectal Dis* 2009;19:122-128.

2. Tiwari A, Sharma H, Qamar K, Sodeman T, Nawras A. Recognition of extraperitoneal colonic perforation following colonoscopy: a review of the literature. *Case Rep Gastroenterol* 2017;11:256-264.
3. Lüning TH, Keemers-Gels ME, Barendregt WB, Tan AC, Rosman C. Colonoscopic perforations: a review of 30,366 patients. *Surg Endosc* 2007;21:994-997.
4. Abdalla S, Gill R, Yusuf GT, Scarpinata R. Anatomical and Radiological Considerations When Colonic Perforation Leads to Subcutaneous Emphysema, Pneumothoraces, Pneumomediastinum, and Mediastinal Shift. *Surg J (N Y)* 2018;4:7-13.
5. Lohsiriwat V. Colonoscopic perforation: incidence, risk factors management and outcome. *World J Gastroenterol* 2010;16:425-430
6. Ignjatović M, Jović J. Tension pneumothorax, pneumoretroperitoneum, and subcutaneous emphysema after colonoscopic polypectomy: a case report and review of the literature. *Langenbecks Arch Surg* 2009;394:185-189.
7. Maunder RJ, Pierson DJ, Hudson LD. Subcutaneous and mediastinal emphysema, pathophysiology diagnosis and management. *Arch Intern Med* 1984;144:1447-1453.
8. Panteris V, Haringsma J, Kuipers EJ. Colonoscopy perforation rate, mechanisms and outcome: from diagnostic to therapeutic colonoscopy. *Endoscopy* 2009;41:941-951.
9. Khan M, Ijaz M, Bukhari S, Dirweesh A, Christmas D. Post-Colonoscopy Colonic Perforation Presenting With Subcutaneous Emphysema: A Case Report. *Gastroenterology Res* 2017;10:135-137.
10. Lee HS, Park HH, Kim JS, Kang SH, Moon HS, Sung JK, Lee BS, Jeong HY. Pneumoretroperitoneum, Pneumomediastinum, Pneumothorax and Subcutaneous Emphysema after Diagnostic Colonoscopy. *Korean J Gastroenterol* 2017;70:145-149.
11. Cirt N, de Lajarte-Thirouard AS, Olivié D, Pagenault M, Bretagne JF. Subcutaneous emphysema, pneumomediastinum, pneumoperitoneum and retroperitoneum following a colonoscopy with mucoscopy. *Gastroenterol Clin Biol* 2006;30:779-782.