



# How Can We Diagnose Pre-malignant Solitary Cecal Ulcer?

## Pre-malign Soliter Çekal Ülseri Nasıl Tanırız?

© Bahar Büşra Özkan<sup>1</sup>, © Kadri Güleşçi<sup>2</sup>, © Nazan Aksoy<sup>3</sup>, © Yüksel Altinel<sup>4</sup>

<sup>1</sup>Ondokuz Mayıs University Faculty of Medicine, Samsun, Turkey

<sup>2</sup>Ordu University Faculty of Medicine, Training and Research Hospital, Department of Radiology, Ordu, Turkey

<sup>3</sup>Ordu University Faculty of Medicine, Training and Research Hospital, Department of Pathology, Ordu, Turkey

<sup>4</sup>Ordu University Faculty of Medicine, Training and Research Hospital, Department of General Surgery, Ordu, Turkey

### ABSTRACT

A 75-year-old woman presented with a 1-month history of right lower quadrant pain and constipation. Physical examination revealed tenderness to palpation. The patient had no history of inflammatory bowel disease. The colonoscopy displayed marked partial obstruction of the cecum with a large ulcerated area and surrounding friable epithelium in the medial cecal region. Microscopic evaluation of the biopsy specimens revealed an acute ulcer with granulation tissue and overlying fibrinopurulent debris. There was no evidence of granulomatous inflammation or crypt abscesses suggesting inflammatory bowel diseases, except the atypical epithelial cells. Additionally, abdominopelvic tomography showed a suspicious cecal tumor underlying a thickened bowel wall and mesocolic lymph adenopathy. Subsequently, we performed right hemicolectomy due to clinical obstruction. No complications were observed during postoperative follow-up. The pathology result confirmed cecal ulcer with low-grade dysplasia.

**Keywords:** Solitary cecal ulcer, dysplasia, colonoscopy, hemicolectomy

### ÖZ

Yetmiş beş yaşında kadın hasta, bir aydır olan ve giderek artan sağ alt kadranda ağrısı ve kabızlık şikayetiyle acil servisimize başvurdu. Fizik muayenede sağ alt kadranda hassasiyet tespit edildi. Batın bilgisayarlı tomografi görüntülemesi ise sağ kolonda öncelikle kolon kanseri ile uyumlu duvar kalınlaşması olduğunu ve mezenterik yağ dokusu içinde birkaç adet lenf nodu olduğunu saptadı. Hem klinik hem de radyolojik bulgularla kolon kanseri şüphesi olması nedeniyle hastaya kolonoskopi yapıldı. Çekumda parsiyel tukanıklığa yol açan geniş tabanlı ülser saptandı. Alınan biyopsinin sonucu atipik epitel fragmanlarıyla beraber ülser ve ülser zemininde enflamatuvar debris olarak değerlendirildi. Hastaya sağ hemikolektomi yapıldı. Patoloji değerlendirmesinde submukozaya sınırlı ülser, enflamatuvar lenf nodları ve mukoza epitelinde hafif displazi tespit edildi. Postoperatif dönemde takiplerinde sorun izlenmedi.

**Anahtar Kelimeler:** Soliter çekal ülser, displazi, kolonoskopi, hemikolektomi

## Introduction

Uncomplicated solitary cecal ulcer is usually diagnosed during laparotomy, even though colonoscopy is the best diagnostic method. The first condition considered in the differential diagnosis of cecal ulcer is usually carcinoma. Colonoscopy is reported to play a key role in the diagnosis of ileocecal ulcers.<sup>1,2</sup> In this study, we discuss a patient with a premalignant lesion on the ulcer base that showed inconsistency between colonoscopy results and suspicious radiology findings.

## Case Report

A 75-year-old female patient was admitted to our emergency department with complaints of progressive pain in the right lower quadrant and constipation for one month. The patient consented to this case report being published. She had no history of systemic disease other than hypertension. There was no hereditary cancer in her family history. On physical examination, the patient showed tenderness in the right lower quadrant. Laboratory tests results were



Address for Correspondence/Yazışma Adresi: Yüksel Altinel MD

University of Health Sciences, İstanbul Bağcılar Training and Research Hospital, Clinic of General Surgery, İstanbul, Turkey

Phone: +90 543 438 89 73 E-mail: dryukselaltinel@gmail.com ORCID ID: orcid.org/0000-0003-0113-4839

Received/Geliş Tarihi: 08.08.2017 Accepted/Kabul Tarihi: 26.09.2017

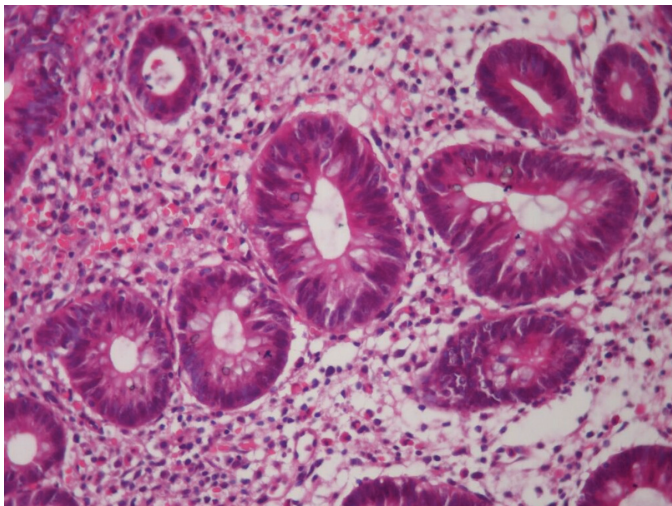
leukocyte count: 12.170/mm<sup>3</sup>, C-reactive protein: 12.2 mg/L, carcinoembryonic antigen: <0.411 mg/L, cancer antigen 19-9: 4.53 mg/L, and hemoglobin: 11 mg/L. Abdominal radiographs revealed severe gas, and abdominal ultrasonography showed a suspicious lesion appearing as a false kidney on the right side of the abdomen. Full abdominal/pelvic computed tomography with oral and intravenous contrast was performed due to suspected colon cancer and revealed thickening of the ascending colon wall consistent with colon cancer as well as several lymph nodes, the largest 9 mm in diameter, in the mesenteric fat tissue. Colonoscopy was performed for suspected colon cancer based on both the clinical and radiological findings. Results of the biopsy indicated atypical epithelial fragments with inflammatory debris on the ulcer and ulcer floor. The patient underwent right hemicolectomy and functional end-to-side ileocolonic anastomosis. Two ulcers 1 cm in diameter and limited to the submucosa and 11 lymph nodes, the largest 1 cm in diameter, were detected in the obtained specimen. There were also reactive changes and mild dysplasia (low-grade dysplasia) in the mucosal epithelium surrounding the ulcer (Figure 1, 2). The patient experienced no problems in the postoperative period.

## Discussion

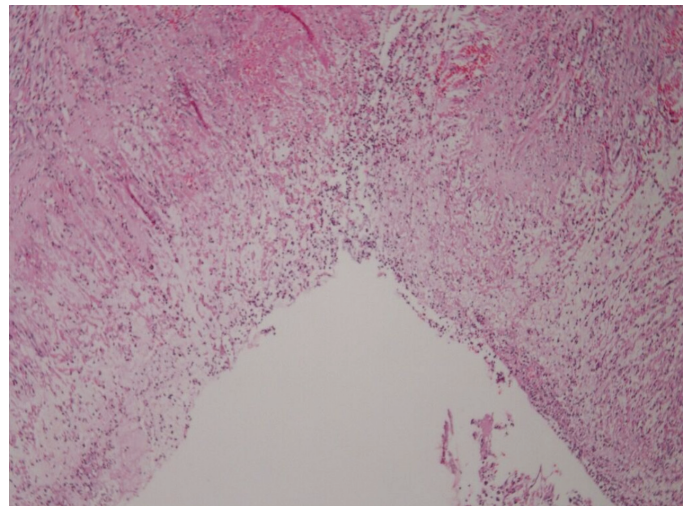
Solitary cecal ulcer may appear on computed tomography as thickening of the cecum or ascending colon, thus mimicking cecal carcinoma. Although colonoscopy is the best diagnostic method, it is rarely diagnosed preoperatively because the patients usually undergo surgery for suspected carcinoma, appendicitis, or diverticulitis. As carcinoma is the most common cause of cecal ulcer, it must also be the first excluded in the differential diagnosis. Wedge resection or right hemicolectomy is recommended for patients

with suspected malignancy.<sup>1</sup> Due to clinical evidence of obstruction and ongoing suspicion of carcinoma, we decided to do a right colectomy.

In a retrospective study investigating the importance of colonoscopy in diagnosis of ileocolic ulcer, endoscopic and histopathologic diagnoses were consistent in 78.8% of 52 patients with ileocecal ulcer after colonoscopy, versus only 17.3% before colonoscopy. This was interpreted as evidence of the key role of colonoscopy in the diagnosis of ileocecal ulcers. The incidence of cecal carcinoma among the patients was reported as 4.4-8.2%, and the authors stated that high-grade cecal carcinoma should be suspected in cases with ulcers of the cecum, which are larger than 2.5 cm and have an irregular and crater-like appearance and irregular borders.<sup>2</sup> In our case, we first evaluated the patient with colonoscopy, a less invasive diagnostic method. The biopsy report indicated inflammatory ulcer with atypical epithelial cells. We decided to perform hemicolectomy due to clinical and radiological suspicion of carcinoma. Although the patient's age, clinical presentation, and findings in all imaging modalities suggested colonic neoplasms, histopathological examination enabled the diagnosis of idiopathic/solitary cecal ulcer. In another report similar to our case, despite imaging data suggesting carcinoma, idiopathic cecal ulcer was diagnosed with specimen obtained by right hemicolectomy.<sup>3</sup> Occasionally, idiopathic cecal ulcers may be accompanied by incidental appendiceal carcinoids. In a case report from İnce et al.,<sup>4</sup> an ulcer was detected 1.5 cm from the appendiceal orifice and a 0.3 cm antimesenteric carcinoid tumor was found in the appendix. Due to its distal location, the authors believed that the cecal ulcer formation could not be attributed to the appendiceal carcinoid tumor.<sup>4</sup> Although solitary cecal ulcers are not associated with a specific presentation, the most common symptom is localized abdominal pain in the



**Figure 1.** Mild dysplasia in the ulcer base (hematoxylin-eosin, 40 $\times$ )



**Figure 2.** Dense inflammatory cells in the colonic mucosal ulcer and lamina propria (hematoxylin-eosin, 10 $\times$ 2)

right lower quadrant. Other possible complaints include bleeding, constipation, diarrhea, weight loss, and intestinal obstruction. Benign (idiopathic) cecal ulcer is a rarely considered diagnosis, and patients' symptoms may mimic other diseases. Cecal ulcers are detected by colonoscopy; in hemodynamically stable patients, multiple random biopsies should be taken for differential diagnosis of inflammatory conditions such as Crohn's disease and ulcerative colitis, and the other parts of the colon should also be examined for ulcerations.<sup>5</sup>

Interestingly, Ram et al.<sup>6</sup> reported another case in which a 51-year-old patient presented with massive lower gastrointestinal system hemorrhage, and a solitary cecal ulcer was detected during colonoscopy. Because a specific cause could not be identified histopathologically following segmental resection, the specimen was analyzed by polymerase chain reaction and diagnosed as solitary tuberculous cecal ulcer.<sup>6</sup> Tuberculosis is one of the clinical diagnoses that should be considered and investigated before making a diagnosis of idiopathic cecal ulcer.

If a patient's clinical condition and endoscopic biopsy results are consistent with a benign pathology and the ulcer shows signs of healing on follow-up colonoscopic examinations in response to treatment, right hemicolectomy may not be necessary. In the literature, conservative treatment options including follow-up colonoscopy are recommended for patients who do not exhibit a clinical picture of acute abdomen and whose colonoscopic biopsy specimens show benign inflammatory changes. Surgical intervention is the first line of treatment in patients with symptoms suggesting signs of acute abdomen, such as peritonitis, perforation, and hemorrhage or suspected malignancy.<sup>5</sup> In summary, we observed that atypical cellular changes may occur at the

base of idiopathic ulcers as a result of intense inflammatory reactions in the colon wall, leading to premalignant lesions. Therefore, it is important to closely follow patients with solitary cecal ulcers and to consider emergency surgical interventions when necessary.

### Ethics

**Informed Consent:** Was taken.

**Peer-review:** External and internal peer-reviewed.

### Authorship Contributions

Surgical and Medical Practices: Y.A., Concept: Y.A., Design: Y.A., Data Collection or Processing: N.A., Analysis or Interpretation: Y.A., Literature Search: K.G., Writing: B.B.Ö.

**Conflict of Interest:** No conflict of interest was declared by the authors.

**Financial Disclosure:** The authors declared that this study received no financial support.

### References

1. Atilla K, Güler S, Gönen C, Saroğlu S, Bora S. Benign solitary cecal ulcer: a condition that mimics plastron appendicitis. *Ulus Travma Acil Cerrahi Derg* 2010;16:579-581.
2. Cai J, Li F, Zhou W, Luo HS. Ileocecal ulcer in central China: case series. *DigDisSci* 2007;52:3169-3173.
3. Gillespie JS, McGovern JM. Solitary caecal ulcer syndrome. *Clin Radiol* 2000;55:894-895.
4. İnce V, Barut B, Karakaş S. Co-existence of idiopathic cecal ulcer and incidental appendix carcinoid tumor. *Ulus Cerrahi Derg* 2016;32:285-286.
5. Chi KD, Hanauer SB. Benign solitary cecal ulcer: a case report and review of the literature. *Dig Dis Sci* 2003;48:2207-2212.
6. Ram D, Karthikeyan VS, Sistla SC, Ali SM. Solitary tubercular caecal ulcer causing massive lower gastrointestinal bleed: a formidable diagnostic challenge. *BMJ Case Rep* 2014;bcr2013201657.