



Prolapsed Ano-Rectal Neoplastic Polyps in Elderly Patients: Our Experience

Yaşlı Hastalarda Anüsten Prolabe Olan Anorektal Neoplastik Polipler: Deneyimlerimiz

© Zeynep Özkan¹, © Ahmet Bozdağ¹, © Ahmet Kılıçaslan², © Ayşe Nur Gönen¹, © Barış Gültürk¹, © Ulaş Aday³, © Abdullah Büyük¹

¹University of Health Sciences, Elazığ Training and Research Hospital, Clinic of General Surgery, Elazığ, Turkey

²University of Health Sciences, Elazığ Training and Research Hospital, Clinic of Pathology, Elazığ, Turkey

³University of Health Sciences, Elazığ Training and Research Hospital, Clinic of Gastroenterology Surgery, Elazığ, Turkey

ABSTRACT

Colorectal adenomas are polyps which originate from the mucosa and exhibit histopathologic neoplastic features. Although they are usually located in the rectosigmoid segment, they also occur commonly throughout the colon. Increasing dysplasia and malignant potential of adenomas are correlated with their size and villous component and with the patient's age. The prevalence of polyps is variable, and their incidence, size, and degree of dysplasia increase with age. Herein, we present four elderly patients with neoplastic polyps that were prolapsed from the anus, caused clinical symptoms and signs that were mistaken for hemorrhoids, and were treated by transanal excision.

Keywords: Anorectal neoplastic polyp, prolapsed, transanal excision

ÖZ

Kolorektal adenomlar, mukozadan kaynaklanan ve histolojik olarak neoplastik özellikler gösteren poliplerdir. Çoğunlukla rektosigmoid bölgede görülmelerine rağmen tüm kolonda sık olarak görülür. Artan displazi ve malignite potansiyeli adenomun boyutu, içerdiği villöz komponent ve hasta yaşı ile ilişkilidir. Adenomatöz poliplerin prevalansı değişkendir, yaş ilerledikçe poliplerin görülme sıklığı, büyüklüğü ve displazi gelişme oranı artar. Biz de bu yazımızda klinik semptom ve bulguları hemoroid ile karışan, transanal eksizyon yaptığımız anüsten prolabe neoplastik polipleri olan dört yaşlı olguyu sunmaya çalıştık.

Anahtar Kelimeler: Anorektal neoplastik polip, prolapsus, transanal eksizyon

Introduction

Colorectal neoplastic polyps and adenomas are structures that originate from the mucosa and exhibit histological neoplastic features. Adenomas are potentially malignant and are classified by the World Health Organization (WHO) as tubular, villous, and tubulovillous.¹ The incidence in the general population is about 5-10% and increases in older individuals, reaching 40-50% in those over 60 years of age.^{2,3} They develop most commonly in the rectosigmoid region, are usually asymptomatic, and are detected incidentally during colonoscopy.⁴ In one study, adenomas accounted for 70%

of polyps removed by colonoscopy.⁵ Most can be removed completely and safely by polypectomy during colonoscopy, and studies have demonstrated that the excision of adenomatous polyps prevents colorectal cancer.⁶ Dysplasia is present to varying degrees in all adenomas. Degree of dysplasia and malignant potential are correlated with the patient's age and the adenoma's size and villous component. The prevalence of adenomatous polyps is variable, and the incidence, size, and rate of development of polyps increase with age.^{7,8} Polyps protruding from the anus may mimic benign anorectal diseases and cause treatment delay in elderly patients, which in turn increases the malignant



Address for Correspondence/Yazışma Adresi: Ahmet Bozdağ MD,
University of Health Sciences, Elazığ Training and Research Hospital, Clinic of General Surgery, Elazığ, Turkey
Phone: +90 533 652 51 63 E-mail: abozdag80@hotmail.com ORCID ID: orcid.org/0000-0003-1973-2511
Received/Geliş Tarihi: 15.01.2018 Accepted/Kabul Tarihi: 03.04.2018

potential. The aim of this study was to present four patients over 65 years of age with prolapsed anorectal polyps which we treated by transanal excision.

Patients who underwent transanal excision of polyps prolapsed from the anal canal between June 2015 and December 2017 in the general surgery unit of the Health Sciences University Elazığ Training and Research Hospital were retrospectively screened. The patients' demographic data, comorbid conditions, physical examination findings, and surgical notes were obtained from their medical records. Pathology reports were reviewed and data were recorded. Patients who could be reached by phone for follow-up were included in the study. Duration of postoperative follow-up was expressed in months. Six patients underwent transanal excision during the study period, but 2 patients who were lost to follow-up were excluded from the study. The clinical and pathological features of the patients are summarized in Table 1. Patients were informed about the study and written informed consent forms were obtained.

Case Reports

Case 1

A 65-year-old male patient was evaluated for a sporadically hemorrhagic mass protruding from the anal canal for approximately two years. On physical examination with the patient in prone position, a prolapsed, 2 cm mobile mass that looked like a hemorrhoid was detected at 3 o'clock. Laboratory test results were within normal range. A diminutive polyp was detected at the splenic flexure on pancolonoscopy, and polypectomy was performed. The hemorrhagic polyp protruding from the anal canal was removed by transanal excision under spinal anesthesia. The splenic flexure polyp was identified in histopathological examination as a hyperplastic polyp, while the polyp excised from the anal canal was identified as a serrated adenoma (Figure 1A).

Case 2

A 90-year-old female patient was evaluated for a 3 month history of rectal bleeding and a palpable mass in the anal region during defecation. A 2 cm hemorrhagic, mobile mass

was detected on the anterior midline. On colonoscopic evaluation, a 0.2 cm polyp was detected in the ascending colon and polypectomy was performed. Abdominal ultrasonography revealed bilateral renal cysts and grade 2 hydronephrosis in the left kidney. Hemoglobin was 13.1 g/dL and other biochemical values were normal. The polyp was removed by transanal excision and identified in pathologic evaluation as a tubular adenomatous polyp with low-grade dysplasia. There was no dysplasia in the polyp stalk (Figure 1B).

Case 3

A 70-year-old female patient was evaluated for complaints of rectal bleeding, constipation, and mass that protruded from the anus during defecation for the last 6 months. The patient also had a history of ischemic heart disease and chronic obstructive pulmonary disease. Physical examination revealed a localized, mobile mass at the border of the distal rectum and anal canal which prolapsed from the anus upon straining. Tumor markers were within normal range. Total colonoscopy revealed a polypoid lesion surrounding one third of the rectum from the anus and covering an area of approximately 10 cm, and a biopsy was performed. The biopsy report indicated tubulovillous adenoma. Computed tomography with oral, rectal, and intravenous contrast revealed wall thickening in a 5 cm rectal segment near the anal canal. Under spinal anesthesia, dilute adrenaline was injected into the submucosal space. Beginning from the anal canal, clean surgical margins were achieved by transanal excision of the mass and underlying muscular layer as a single piece. No postoperative complications occurred. The 7.5x5.4x2.7 cm mass was determined in pathologic examination to be a villous adenoma. No recurrence was observed during 24 months of follow-up (Figure 1C).

Case 4

An 84-year-old female patient was evaluated for complaints of rectal bleeding, foul-smelling anal discharge, and a palpable mass for 4 months. On examination with the patient in knee-elbow position, a polypoid mass that prolapsed from the anal canal upon straining was detected at 6 o'clock,

Table 1. Demographic and clinical data of the patients

Patient	Sex	Age (years)	Polyp size (cm)	Additional polyp type	Surgery performed	Histopathology of the anorectal polyp	Follow-up time (months)
Case 1	Male	65	2.5	Hyperplastic adenoma	Transanal excision	Serrated adenoma	24
Case 2	Female	90	2	Tubular adenoma	Transanal excision	Tubular adenoma and low-grade dysplasia	9
Case 3	Female	70	10	No	Transanal excision	Villous adenoma	8
Case 4	Female	84	2.5	Serrated adenoma	Transanal excision	Villous adenoma and adenocarcinoma	15

as well as prolapsed hemorrhoids. The polypoid mass was 2.5x2.5 cm in size, foul-smelling, and had a necrotic surface and erosion. A total of three millimetric polyps in the descending colon and sigmoid colon were detected during colonoscopy and removed by polypectomy. Laboratory parameters were within normal range. Transanal polyp excision and hemorrhoidectomy were performed and the patient was discharged without complication. Pathologic examination revealed adenocarcinoma arising from villous adenoma, with invasion of the stalk. The surgical margin

was 2.1 mm, there was no lymphovascular invasion, and the mass was well differentiated; therefore, no further treatment was recommended (Figure 1D, Figures 2A and 2B).

Discussion

Tissue extending from the intestinal mucosa or submucosa into the lumen is called a polyp. Polyps that exhibit epithelial atypia on histopathological evaluation are called neoplastic polyps. Neoplastic polyps are also referred to as adenomas. A certain level of dysplasia is the main

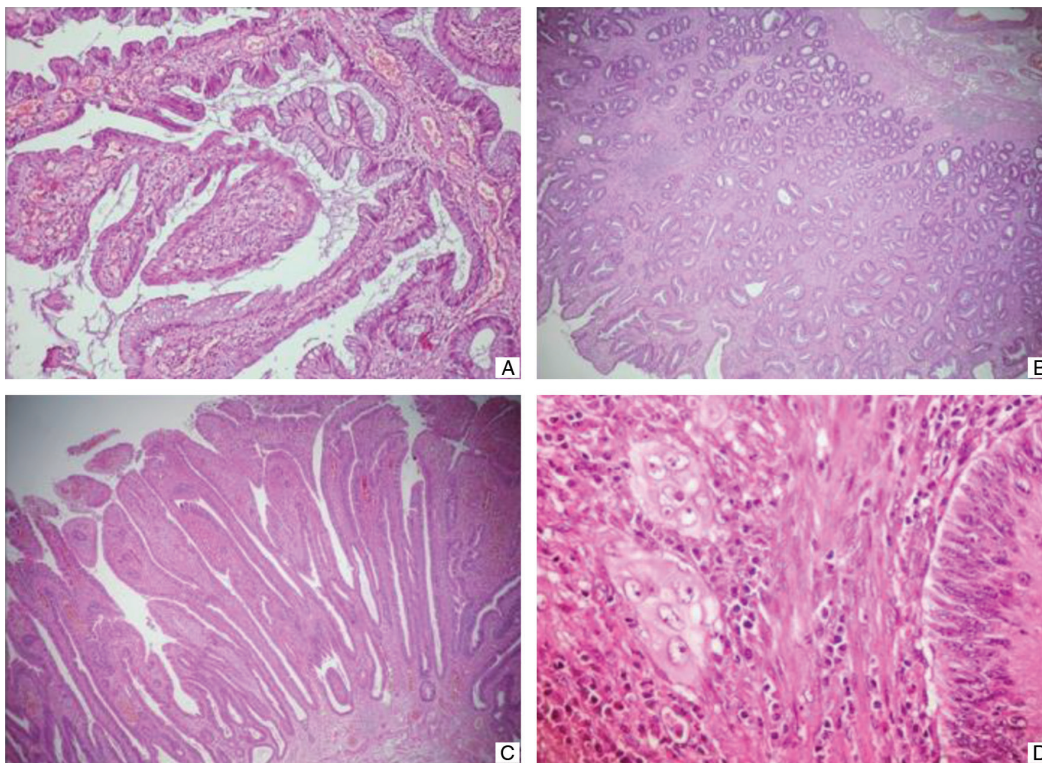


Figure 1. Microscopic images of anal polyps stained with hematoxylin and eosin (H&E). A) Serrated adenoma (x100), B) Tubular adenoma (x40), C) Villous adenoma (x100), D) Villous adenoma containing an invasive carcinoma focus (x400)

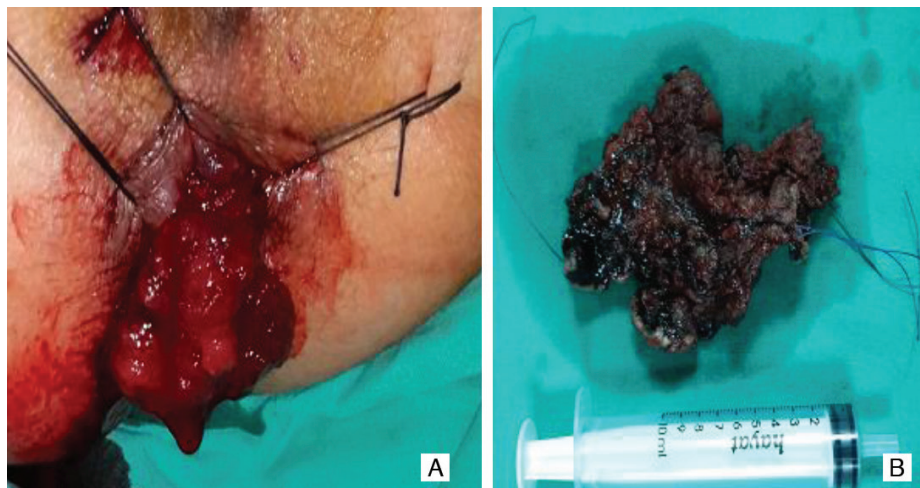


Figure 2. Images of patient 4. A) Preoperative image of giant, hemorrhagic rectal villous adenoma prolapsed from the anus, B) The excised specimen

criterion for adenomas; without dysplasia, a diagnosis of adenoma is invalid.⁹ Aging is accompanied by increases in the frequency, size, and dysplasia of polyps in the digestive system.¹⁰ The prevalence of adenomatous polyps increases with age, as do the polyps' size and degree of dysplasia.^{7,10} WHO defines the elderly population as those over 65 years of age; therefore, we included patients aged 65 or older in our study.¹¹ Male gender and obesity are recognized risk factors for adenomatous polyps.¹⁰ The patients presented herein were of advanced age; however, in contrast to the literature, none were obese and only one was male.

Colonic adenomas are commonly located in the rectosigmoid region and are generally smaller than 1 cm in size. The size of adenomas varies based on its composition, with the proportion smaller than 1 cm reported as 77% for tuberculous adenomas, 25% for villous adenomas, and 14% for tubulovillous adenomas. Non-neoplastic polyps are usually less than 5 mm in size.¹⁰ Adenomas located in the low rectum and anal canal, as seen in our cases, are less common. All of the adenomas in our patients were larger than 1 cm, which we attribute to late awareness of symptoms and reluctance to see a doctor due to the patients' age.

Patients with neoplastic polyps are at increased risk of developing new adenomas and cancer in the future. Of patients who undergo polypectomy, the American Society for Colorectal Cancer Task Force defined those with polyps smaller than 10 mm and those with fewer than 3 polyps as the "low-risk" group. Patients with polyps larger than 10 mm, those with 3 or more polyps, and those whose polyps have villous features and/or high-grade dysplasia comprise the "high-risk" group.¹² Follow-up colonoscopies and polypectomies enable the early detection or prevention of future cancers. The American literature recommends a follow-up period of 5-10 years after the first colonoscopy for patients with one or two tubular adenomas smaller than 10 mm without high-grade dysplasia, whereas a follow-up colonoscopy is recommended after 3 years for patients with 3 or more adenomas, polyps larger than 10 mm, and high-grade dysplasia and villous structures.¹³ As in three of our patients, polyps are also frequently detected in colon segments other than the anal region. Due to their age and the presence of neoplastic polyps, such patients should undergo a complete colon examination preoperatively. All of our patients were scheduled for regular follow-up; although we advised the patient with adenocarcinoma to return after 15 months for colonoscopy, she did not return for colonoscopy and oncologic follow-up because she lived in a rural area and had difficulty with transportation.

Colorectal polyps may manifest with various clinical manifestations such as hematochezia, diarrhea with mucous, obstruction, findings associated with intussusception, or

anal prolapse of pedunculated rectal polyps. Because the polyps were very low in three of our patients and large in one patient, they prolapse from the anal canal and the main clinical findings were bleeding and palpable mass.¹⁴

All of our patients were successfully treated transanally under local or regional anesthesia. In recent years, different transanal excision and minimally invasive methods have been implemented successfully in patients with rectal adenomas, which is especially beneficial for elderly patients with high comorbidity and operative risk. Our patients were all elderly, but operative risk was high in one patient. Although the duration of follow-up was not very long (mean 14 months), the lack of recurrence in our patients suggests that this is a suitable treatment approach.

The main criteria for neoplastic change are size, histological type, and degree of dysplasia. In an Italian study of 16 patients with protruding isolated rectal and anal neoplastic polyps who underwent local transanal excision, 2 patients developed postoperative bleeding and urinary retention, and histopathologic examination revealed that 12.5% of the masses were tubular adenomas with no atypia, 18.75% were tubulovillous adenomas with moderate atypical, 50% were tubulovillous adenoma with severe atypia, 12.5% were tubulovillous adenoma with locally invasive foci of adenocarcinoma, and 6.25% were pT1 cloacogenic carcinoma. During a mean follow-up of 21.7 months, one patient had two recurrences, one at 8 months and another 6 months later.¹⁵ In the cases presented here, we detected villous adenoma in one patient, villous adenoma and adenocarcinoma in one, serrated adenoma in one, and tubular adenoma with low-grade dysplasia in one patient.

It is well known that elderly patients presenting with classic hemorrhoid symptoms may have adenomatous polyps prolapsing from the anal canal and they should be evaluated by colonoscopy before surgical intervention. Patients can be treated successfully with transanal excision under the appropriate anesthesia based on the patient's risk/benefit ratio. Histopathologic examination of the excised polyps is imperative and if cancer is detected, further treatment should be planned according to the patient's condition.

Ethics

Informed Consent: Patients were informed about the study and written informed consent forms were obtained.

Peer-review: External and internal peer-reviewed.

Authorship Contributions

Surgical and Medical Practices: Z.Ö., A.B., Concept: U.A., B.G., A.B., Design: Z.Ö., A.N.G., Data Collection or Processing: A.B., B.G., Analysis or Interpretation: A.K., A.B., Literature Search: Z.Ö., A.B., A.N.G., Writing: Z.Ö., A.B.

Conflict of Interest: No conflict of interest was declared by the authors.

Financial Disclosure: The authors declared that this study received no financial support.

References

1. Morson BC, Sobin LH. Histological typing of intestinal tumours In: International Histological Classification of Tumours, No. 15. Geneva: World Health Organization, 1976.
2. Fenoglio-Preiser CM, Hutter RV. Colorectal polyps: pathologic diagnosis and clinical significance. *CA Cancer J Clin* 1985;35:322-344.
3. Lieberman DA, Smith FW. Screening for Colon Malignancy with Colonoscopy. *Am J Gastroenterol* 1991;86:946-951.
4. Terzi C, Canda AE. Kolorektal Polipler ve Polipozis Sendromları, Sayek İ.(editör) Temel Cerrahi. 1.Cilt Ankara: Güneş Kitabevi; 4. Baskı 2013;1397-1406.
5. Konishi F, Morson BC. Pathology of colorectal adenomas: A colonoscopic survey. *J Clin Pathol* 1982;35:830-841.
6. Bond JH. Polyp Guideline: Diagnosis, Treatment, and Surveillance for Patients With Colorectal Polyps. *Am J Gastroenterol* 2000;95:3053-3063.
7. Dölek Y, Karabulut YY, Topal F, Kurşun N. Gastrointestinal poliplerin boyut, lokalizasyon ve histopatolojik tipleri ile değerlendirilmesi. *Endoskopi* 2013;21:31-35.
8. O'Brien MJ, Winawer SJ, Zauber AG, Gottlieb LS, Sternberg SS, Diaz B, Dickersin GR, Ewing S, Geller S, Kasimian D. The National Polyp Study: Patient and polyp characteristics associated with high-grade dysplasia in colorectal adenomas. *Gastroenterology* 1990;98:371-379.
9. Yamaner S. Kolorektal polipler. *Türk Kolon Rektum Hastalıkları Dergisi* 2007;17:1-8.
10. Korkmaz H, Kendir İC, Akkaya Ö. Evaluation of size, localization and histopathologic structures of colonic polyps. *Endoscopy Gastrointestinal* 2016;13-17.
11. Tezcan S, Seçkiner P. Türkiye'de demografik değişim; yaşlılık perspektifi. Aslan D, Ertem M Editörler. Yaşlı sağlığı sorunlar ve çözümler 1. Baskı. Ankara: Palme Yayıncılık, 2012:1-3.
12. Lieberman DA, Rex DK, Winawer SJ, Giardiello FM, Johnson DA, Levin TR. Guidelines for Colonoscopy Surveillance After Screening and Polypectomy: A Consensus Update by the US MultiSociety Task Force on Colorectal Cancer. *Gastroenterology* 2012;143:844-857.
13. Levin B, Lieberman DA, McFarland B, Andrews KS, Brooks D, Bond J, Dash C, Giardiello FM, Glick S, Johnson D, Johnson CD, Levin TR, Pickhardt PJ, Rex DK, Smith RA, Thorson A, Winawer SJ; American Cancer Society Colorectal Cancer Advisory Group; US Multi-Society Task Force; American College of Radiology Colon Cancer Committee. Screening and surveillance for the early detection of colorectal cancer and adenomatous polyps, 2008: a joint guideline from the American Cancer Society, the US Multi-Society Task Force on Colorectal Cancer, and the American College of Radiology. *Gastroenterology* 2008;134:1570-1595.
14. Ögüş M, Dinçkan A, Gelen T, Aksoy N. Anüsten prolabe olan inen kolon tümörü: Olgu Sunumu. *Ulus Travma Acil Cerrahi Derg* 2005;11:247-249.
15. Fiducia G, Gandolfo L, Bosco V. Protruding isolated rectal and anal neoplastic polyps removed by local transanal excision: our experience with 16 cases. *Chir Ital* 2008;60:227-232.