

Amyand's Hernia: Report of a Case

Amyand Fıtığı: Olgu Sunumu

DOĞAN ALBAYRAK¹, ABDİL CEM İBİŞ², EYÜP YELDAN², AHMET RAHMİ HATİPOĞLU²

¹Kızıltepe State Hospital General Surgery Department Mardin, ²Trakya University Medical Faculty General Surgery Department Edirne

ÖZET

İnguinal fıtık kesesi içerisinde apendiks vermiformis bulunması durumu Amyand fıtığı olarak 1735 yılında Claudius Amyand tarafından tanımlanmıştır. Bu cerrahi tarihinde yapılmış ilk apendektomidir. Tüm kasık fıtığı operasyonları göz önüne alındığında fıtık kesesi içinde normal apendiks bulunması insidansı %0.5-1 olmakla birlikte, akut apandisit bulunması insidansı %0.1'dir. Yazımızda inkarsere sağ inguinal fıtığı nedeniyle cerrahi uygulanan ve fıtık kesesi içerisinde akut apandisit tespit edilen olgu sunuldu. İnsidans, uygulanabilecek cerrahi metod ve tanı yöntemlerinin tartışılmasını ayrıca literatürün gözden geçirilmesini amaçladık.

Anahtar kelimeler: Akut apandisit, Fıtık

ABSTRACT

Vermiform appendix in an inguinal hernia sac was named as Amyand's hernia by Claudius Amyand in 1735. This was the first appendectomy in the history of surgery. Regarding all inguinal hernia operations, the incidence of finding an ordinary appendix within the inguinal sac is 0.5-1%, while finding an acute inflamed appendix is 0.1%. In our article, we report a case operated for right incarcerated inguinal hernia and turned out to have an acute appendicitis within the inguinal sac. We discuss the incidence, surgical method preoperative diagnostic methods and review the literature.

Key words: Acute appendicitis, Hernia

Başvuru Tarihi: 08.08.2009, Kabul Tarihi: 31.08.2009

✉ Dr. Doğan Albayrak

Hastane Cad. Medrese Sk. Şenyurt Demircan Ap.

No:7 Kat:1 Daire:1 Kızıltepe/Mardin-Türkiye

Tel: 0505.2170482

e-mail: doganalbayrak@mynet.com

Kolon Rektum Hast Derg 2009;19:181-183

Introduction

The presence of the appendix within the sac of an inguinal hernia is a rare medical condition, which is named as 'Amyand's hernia'.¹ Regarding all inguinal hernia operations, incidence of finding an ordinary appendix within the inguinal sac is 0.5-1%, meanwhile incidence of finding an acute inflamed appendix is 0.1%.^{2,3} In the light of literature data, we sought to evaluate a patient operated for incarcerated right-sided inguinal hernia, whose inguinal sac included the appendix, and we also discussed the proper treatment modality.

Case Presentation

A 5-year-old boy was brought to the emergency department due to the right-sided inguinal pain for the last 10 hours. Physical examination revealed a 4x2 cm, tender mass in the right inguinal region. The white blood cell count was 15400/mm³. Surgical intervention was planned due to the diagnosis of incarcerated right-sided inguinal hernia. The inguinal sac contained the appendix vermiformis and some serous fluid. The incarcerated appendix found to be inflamed. Appendectomy was performed. High ligation of hernial sac was added. The patient was discharged on the second postoperative day. The follow-up was uneventful.

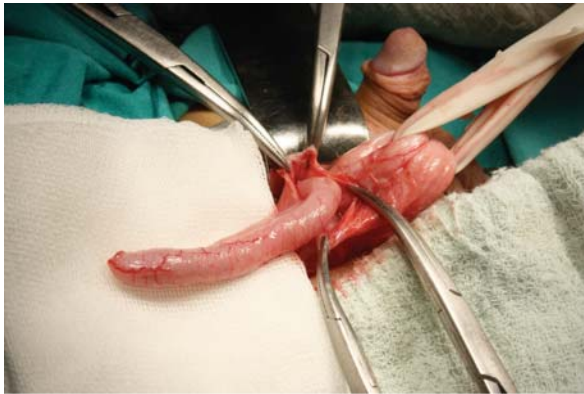


Figure. İnkarsere fitik kesesi açıldı.

Discussion

Appendectomy is one of the most frequent surgical operations performed safely worldwide. The first successful appendectomy was performed by an English

surgeon Cladius Amyand (1680-1740).¹ The patient was operated for incarcerated inguinal hernia and fecal fistula. He underwent appendectomy and inguinal hernia repair, thus the condition was called Amyand's hernia.¹ Amyand's hernia was described over 270 years ago, however the condition is still poorly known among surgeons.^{1,4-6}

Patient's history and physical examination findings usually lead to incarcerated hernia with local peritonitis.⁴⁻⁶ Differential diagnosis should be made between Amyand's hernia and pathologies like hemorrhagic testicle tumors, testicular torsion, acute hydrosoel, inguinal lymphadenitis, focal panniculitis and epididimitis.⁷ Ultrasonography and computerized tomography [CT] could be used for preoperative differential diagnosis.⁸ However, CT scanning is not a routine procedure. Amyand's hernia is difficult to be diagnosed preoperatively. Usually the definitive diagnosis can be made only after the inguinal sac is opened.

Appropriate treatment approach for Amyand's hernia, depends on the condition of appendix found inside the hernia sac. If the appendix found within the sac is inflamed or perforated, appendectomy should be performed. If appendix vermiformis is found inside the hernia sac, it is controversial to perform an appendectomy during routine hernia repair, regarding the rise of infection risk.⁷⁻¹⁰ Ofili⁹, reported that he observed no recurrent hernia or wound infection within 11 patients diagnosed with Amyand's hernia, after appendectomy. In contrary, Carey¹⁰ reported that Amyand's hernia cases had a higher risk of wound infection and fistula formation through appendix stump after appendectomy, because of the existent contamination and increased inflammatory response by the synthetic patch used for inguinal repair. Thus he did not recommend appendectomy if there is no evidence of appendicitis. Especially for the elderly patients, due to prolonged surgery, comorbidities, and low rate of appendicitis at that age group, prophylactic appendectomy is not advised.¹⁰

Despite being a rare condition difficult to diagnose, Amyand's hernia should be considered in the differential diagnosis for incarcerated inguinal hernia. Appendectomy must definitely be performed, if evidence of acute appendicitis is found within the hernia sac.

References

1. Hutchinson R. Amyand's Hernia. *J R Soc Med.* 1993;86:104-5.
2. Logan MT, Nottingham JM. Amyand's hernia: A case report of an incarcerated and perforated appendix within an inguinal hernia and review of the literature. *Am Surg* 2001;67:628-29.
3. House MG, Goldin SB, Chen H. Perforated Amyand's hernia. *South Med J* 2001;94:496-98.
4. Priego P, Lobo E, Moreno I, *et al.* Acute appendicitis in an incarcerated crural hernia: analysis of our experience. *Rev Esp Enferm Dig.* 2005;97(10):707-15.
5. Aminian A, Mirsharifi R, Kalhor M, Dashti H. Amyand hernia. *Indian J Gastroenterol.* 2008;27(5):209.
6. Anagnostopoulou S, Dimitroulis D, Troupis TG, *et al.* A. Amyand's Hernia: A Case Report. *World J Gastroenterol* 2006;12:4761-63.
7. Losanoff JE, Basson MD. Amyand hernia: a classification to improve management. *Hernia.* 2008;12(3):325-26.
8. Laermans S, Aerts R, De Man R. Amyand's hernia: inguinal hernia with acute appendicitis. *JBR-BTR* 2007;90:524-25.
9. Ofili OP. Simultaneous appendectomy and inguinal herniorrhaphy could be beneficial. *Ethiop Med. J.* 1991;29:37-38.
10. Carey LC. Acute appendicitis occurring in hernias. A report of 10 cases. *Surgery* 1967;61:236-38.