

Cecal Volvulus: Report of Two Cases

Çekal Volvulus: İki Olgu Sunumu

MUSTAFA HASBAHÇECİ, FATİH BAŞAK, ALİ KILIÇ, ŞAHAP TÜMERDEM, TOLGA CANBAK,
ORHAN ALİMOĞLU

Ümraniye Eğitim ve Araştırma Hastanesi Genel Cerrahi Kliniği, İstanbul-Türkiye

ÖZET

Amaç: Çekal volvulus akut intestinal obstruksiyonun nadir bir sebebi olarak, çekum ve terminal ileumun kendi mezenterleri etrafında ve aksial planda bükülmesidir. Nadir olarak görülmesinin yanında, bilinebilirliğin az olması da tanıda şüpheye ve bunu takiben tedavide gecikmeye yol açmaktadır.

Olgu Sunumları: Bu yazıda iki farklı çekal volvulus olgusunun klinik özellikleri ile sunulması amaçlandı. Birinci olguda daha önceki laparotomilere bağlı adezyonlar, ikinci olguda ise tedavi edilmemiş hipotiroidizm çekal volvulusun en olası sebepleri olarak değerlendirildi. Sağ hemikolektomi ve primer anastomoz her iki hastaya sorunsuz olarak uygulandı.

Sonuçlar: Çekal volvulusun erken tanısı ve acil tedavisi barsakların gangrenöz değişimine engel olabilir. Erken tanı için öncelikle direkt karın grafisi istenmelidir. Çekal volvulusun kesin tanısı için, hastanın klinik özellikleri dikkate alınarak bilgisayarlı tomografi ya da kolonoskopi düşünülebilir. Hastanın genel durumuna bağlı olmak

ABSTRACT

Purpose: Cecal volvulus as an uncommon cause of acute intestinal obstruction is axial twist of the cecum and terminal ileum around their mesentery. In addition to its rarity, lack of familiarity causes diagnostic doubt and consequently delays in treatment.

Case Reports: In this paper, we describe two cecal volvulus cases with their clinical properties. Adhesions caused by previous laparotomies and untreated hypothyroidism were accepted as the most probable causes of the first and second cases, respectively. Right hemicolectomy and anastomosis was applied to both uneventfully.

Conclusions: Prompt recognition and urgent treatment of cecal volvulus may avoid gangrenous changes of the bowel. Abdominal radiographs should be used primarily for early diagnosis. Depending on clinical findings, computed tomography or colonoscopy can be considered for definitive diagnosis. Resection and anastomosis is the proposed choice of the operation depending on the

Başvuru Tarihi: 15.12.2011, Kabul Tarihi: 08.02.2012

Dr. Mustafa Hasbahçeci

Hırkai Şerif M Keçeci Çeşmesi S Doktorlar

S B Bl 6/7 Fatih 34766 İstanbul - Türkiye

Tel: 0533.3560132

e-mail: hasbahceci@yahoo.com

Kolon Rektum Hast Derg 2012;22:21-24

kaydı ile rezeksiyon ve anastomoz önerilen tedavi seçeneğidir.

Anahtar Kelimeler: *Volvulus, Çekum, Cerrahi*

Introduction

Cecal volvulus (CV) as an uncommon cause of intestinal obstruction is axial twist of the cecum, ascending colon and terminal ileum around their mesenteric pedicle.^{1,2} Although most of the volvulus occurs in the sigmoid colon, cecum is the second in its frequency of occurrence.³ Lack of familiarity with this condition usually causes diagnostic doubt and consequently delays in treatment, which are all contributing factors for development of gangrene with probable high morbidity and mortality.^{3,4} We report two cases of CV describing their presentation, management and subsequent outcome.

Case Descriptions

Case 1

A 55-year-old female patient presented to the Emergency Department with a two day history of severe colicky abdominal pain and obstipation with vomiting. She had appendectomy, cholecystectomy and caesarian section operations. Her medical history was insignificant. Physical examination revealed diffuse abdominal rigidity and rebound tenderness. The laboratory tests showed only leukocytosis with normal biochemical analysis. A plain supine X-ray of the abdomen revealed colonic and small intestinal air-fluid levels. In computed tomography, massive dilatation of the right colon dilated small intestinal segments and the coffee-bean sign indicating CV were detected. Exploratory laparotomy was performed with presumptive diagnoses of CV and mechanical intestinal obstruction, because of the possible adhesions caused by previous laparotomies. At operation, dilated cecum with ischemic changes involving distal ileum was found (Figure 1). Right hemicolectomy and side to side ileotransversostomy was performed. She made an uncomplicated recovery and was discharged on the fifth postoperative day. Histopathology confirmed hemorrhagic infarction on the mucosa and effacement of muscularis propria.

The patient has been followed for two and a half years without any complaint.

general condition of the patient.

Key words: *Volvulus, Cecum, Surgery*

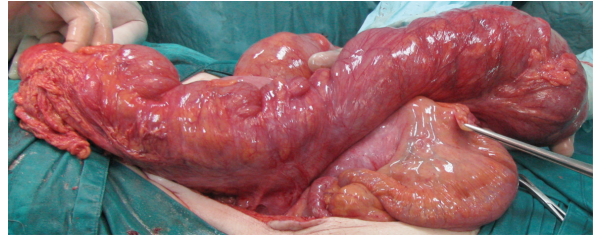


Figure 1. *Intraoperative appearance of CV with minimal ischemic changes on the cecum.*

Case 2

A 59-year-old female patient presented to the Emergency Department with a three day history of mild abdominal pain, obstipation and abdominal distention which were not associated with nausea and vomiting. The patient has not had a prior laparotomy and her medical history was significant for congenital hypothyroidism with mild mental retardation, and previous myocardial infarction. On physical examination, diffuse tenderness without rigidity and rebound tenderness were found. The laboratory analysis was normal except thyroid stimulating hormone level of 18.91 uIU/mL (normal range: 0.49-4.67 uIU/mL). A plain supine abdominal radiograph showed markedly distended loop of bowel with its axis running from the right to the left (coffee-bean sign) and laterally dilated loop of small intestinal segments (Figure 2).

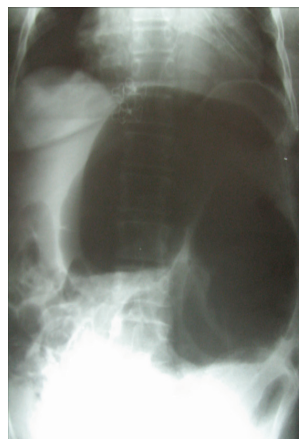


Figure 2. *Distended cecum with its axis running from the right to the left (coffee-bean sign) and laterally dilated loop of small intestinal segments.*

The patient was admitted to the surgical ward, and levothyroxine sodium treatment was initiated immediately for hypothyroidism. A trial of diagnostic and decompressive colonoscopy was planned. At colonoscopy, passage through the proximal transverse colonic segment could not be performed because of the stenosis with concentricity of mucosal folds indicating CV at the level of distal right colon. The decision was made to exploratory laparotomy. The dilated and thin-walled cecum twisting around its mesentery without strangulation, and dilated distal small intestinal segments were seen at laparotomy (Figure 3). Minimal dilatation of the other colonic segments was seen during exploration. Right hemicolectomy and side to side ileotransversostomy was performed. She made an uncomplicated recovery and was discharged on the eighth postoperative day. Histopathology confirmed hyperemia and edema on the mucosa of the resected segments and serosal vascular congestion.

The patient has been followed for one year without any complaint.

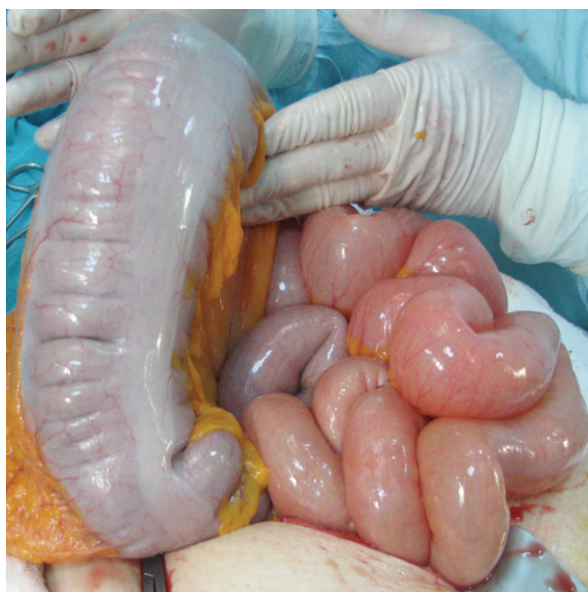

Figure 3. Massive dilatation of the cecum and distal small intestinal segments.

Discussion

Twisting of a loop of bowel and its mesentery on a fixed point at the base is known as volvulus and it may arise in the sigmoid colon, cecum, splenic flexure, and transverse colon, in descending order of frequency.⁴

The underlying etiology and predisposing factors for CV include conditions such as chronic constipation, abdominal masses, pregnancy, prior abdominal surgery, prolonged immobility, constipation and colonoscopy.^{1,3,5} According to the clinical series, previous abdominal surgery was identified as an important contributing factor for CV.³ However, lack of fixation of the right colon, cecum, terminal ileum and mesentery to the posterior parietal peritoneum causing a mobile cecum is primarily required for this twisting to occur.^{4,5} Despite this possible anatomic predisposition in certain individuals, the exact etiology is most likely multifactorial.⁴ In the first case of this paper, we thought that the possible etiology was adhesions due to the previous laparotomies, and for the second case, hypothyroidism may be the triggering factor for the development of CV. Although the evolution of megacolon and pseudovolvulus caused by hypothyroidism to true volvulus is not known to occur, the edematous focus in the bowel may serve as a pivot point upon which the colon may twist.⁶ In the second case, the presence of minimally dilated colonic segments in addition to CV and full recovery after surgical treatment with intense thyroid hormone replacement may connote that hypothyroidism causing megacolon and volvulus is the suspected etiology.

Clinical presentation could be highly variable, ranging from intermittent episodes of abdominal pain to abdominal catastrophe.^{1,4} Preoperative diagnosis of CV is rarely achieved in most cases because of its rarity and nonspecific presentation.^{4,5} It is believed that abdominal radiographs often can be abnormal and detect CV in more than 50 % of the cases.³ The point of the coffee-bean deformity in CV is directed toward the left upper quadrant as our in second case. A dilated ectopic cecum a single air-fluid level in the right lower quadrant, small bowel dilatation and absence of gas in the distal colon are reported as the most commonly visualized abnormalities in CV.^{3,4} So, they can play a critical role in the early evaluation of patients suspected of volvulus. However, computed tomography has been recommended in recent years for the definitive diagnosis of CV.^{4,7} Colonoscopy as a diagnostic and therapeutic modality can be used in selected cases.^{2,4} Colonoscopic reduction for CV is less invasive than surgery, so when the patient's general condition is stable and emergency surgery is not considered as necessary, it may be suggested to perform

the reduction of CV colonoscopically.⁸ This therapeutic modality was not attempted in the first case of our report because of diffuse abdominal rigidity and rebound tenderness. Although it was possible to detect CV in the second case, colonoscopic reduction could not be carried out effectively.

Immediate surgical reduction of the twisted segment is the most effective treatment to prevent progression to necrosis.²⁻⁴ Resection is mandatory for gangrene as in Case 1, and also should be strongly considered when encountering a grossly distended and thin-walled cecum as in Case 2.^{2,3} Following resection, reconstruction as

to anastomosis or ileostomy should be chosen on the basis of the patient's condition and the condition of the bowel at the time of surgery.³

In conclusion, the occurrence of CV is a multifactorial process in the presence of abnormally mobile cecum. Prompt recognition and urgent treatment may avoid gangrenous changes of the bowel. Although abdominal radiographs should play an important role in early diagnosis, computed tomography can be considered for definitive diagnosis of CV. Resection and primary anastomosis is the choice of the operation depending on the general condition of the patient.

References

1. Katoh T, Shigemori T, Fukaya R, *et al.* Cecal volvulus: report of a case and review of Japanese literature. *World J Gastroenterol* 2009;15:2547-9.
2. Majeski J. Operative therapy for cecal volvulus combining resection with colopexy. *Am J Surg* 2005;189:211-3.
3. Consorti ET, Liu TH. Diagnosis and treatment of caecal volvulus. *Postgrad Med J* 2005;81:772-6.
4. Madiba TE, Thomson SR. The management of cecal volvulus. *Dis Colon Rectum* 2002;45:264-7.
5. Valsdottir E, Marks JH. Volvulus: small bowel and colon. *Clin Colon Rectal Surg* 2008;21:91-3.
6. Tran HA, Foy A. Myxedema pseudovolvulus. *J Clin Endocrinol Metab.*, 2006;91:2819-20.
7. Delabrousse E, Sarliève P, Sailley N, *et al.* Cecal volvulus: CT findings and correlation with pathophysiology. *Emerg Radiol* 2007;14:411-5.
8. Ballantyne GH, Brandner MD, Beart RW Jr, *et al.* Volvulus of the colon. Incidence and mortality. *Ann Surg* 1985;202:83-92.